SD-IAP 669

- 1,5 ročný chlapec
- tumor mozgu frontálne vpravo
- fragmenty homogénneho belavoružového tkaniva 40x25x10 mm

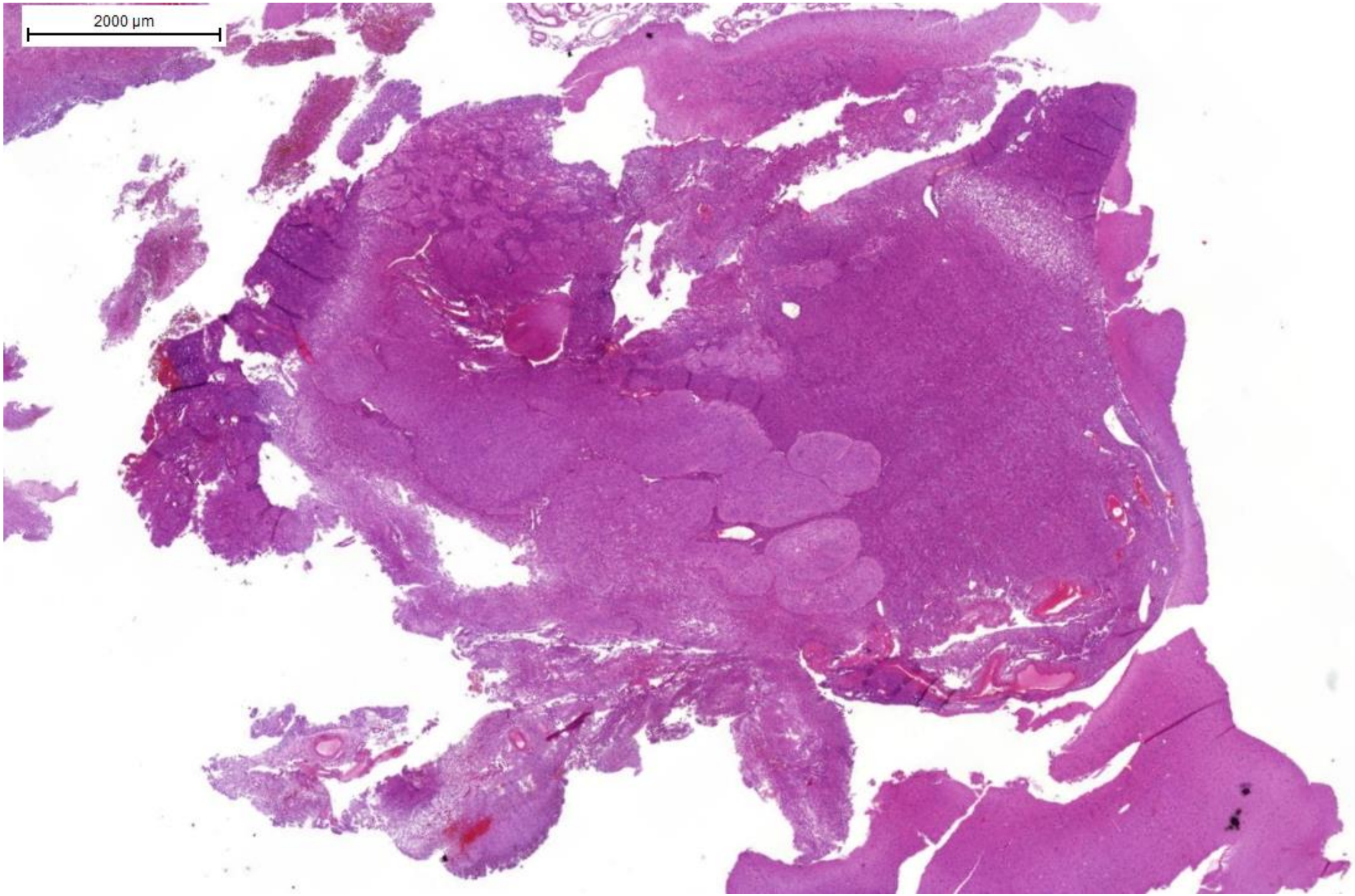
2000 µm

2000 µm

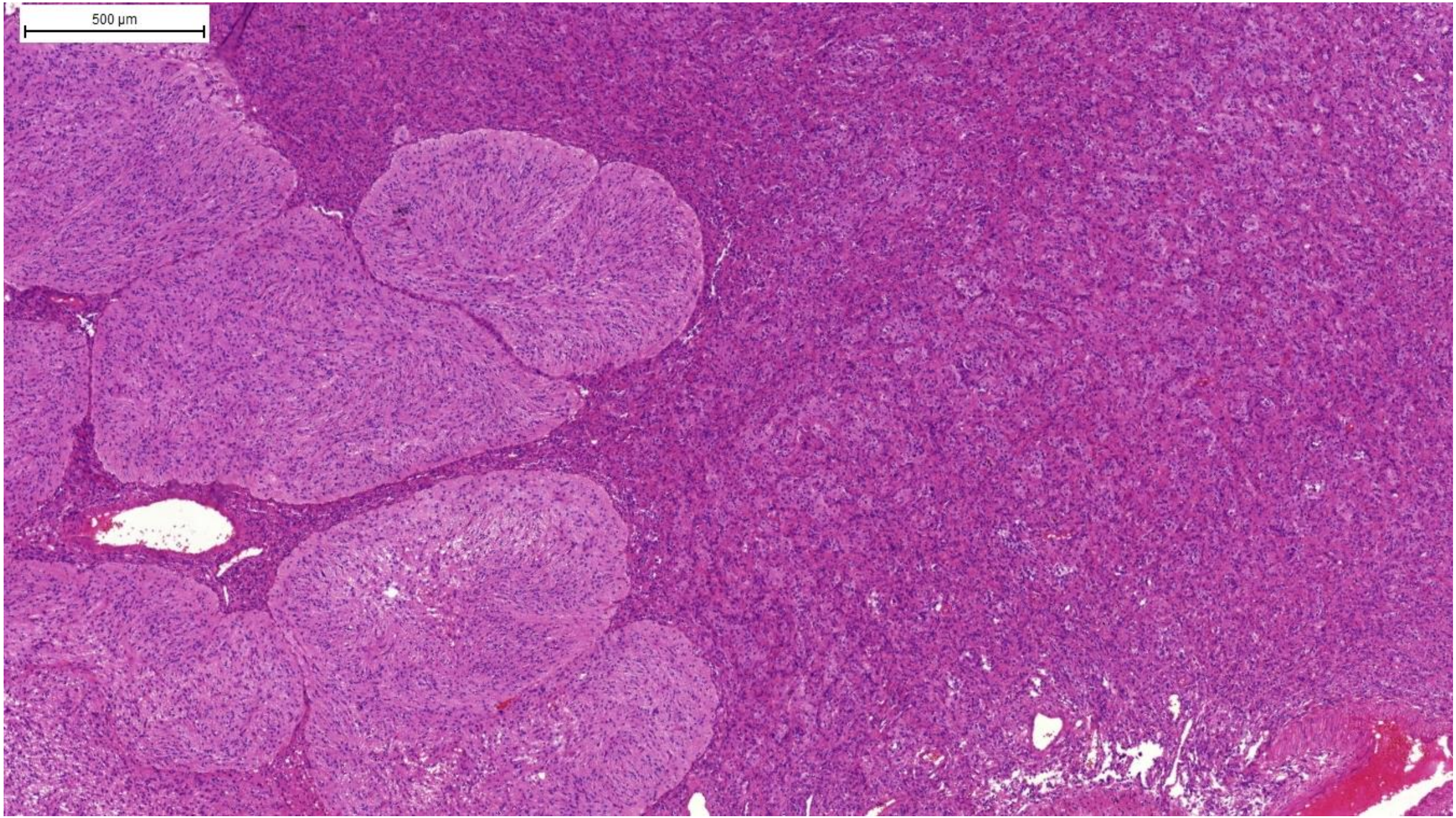
500 µm

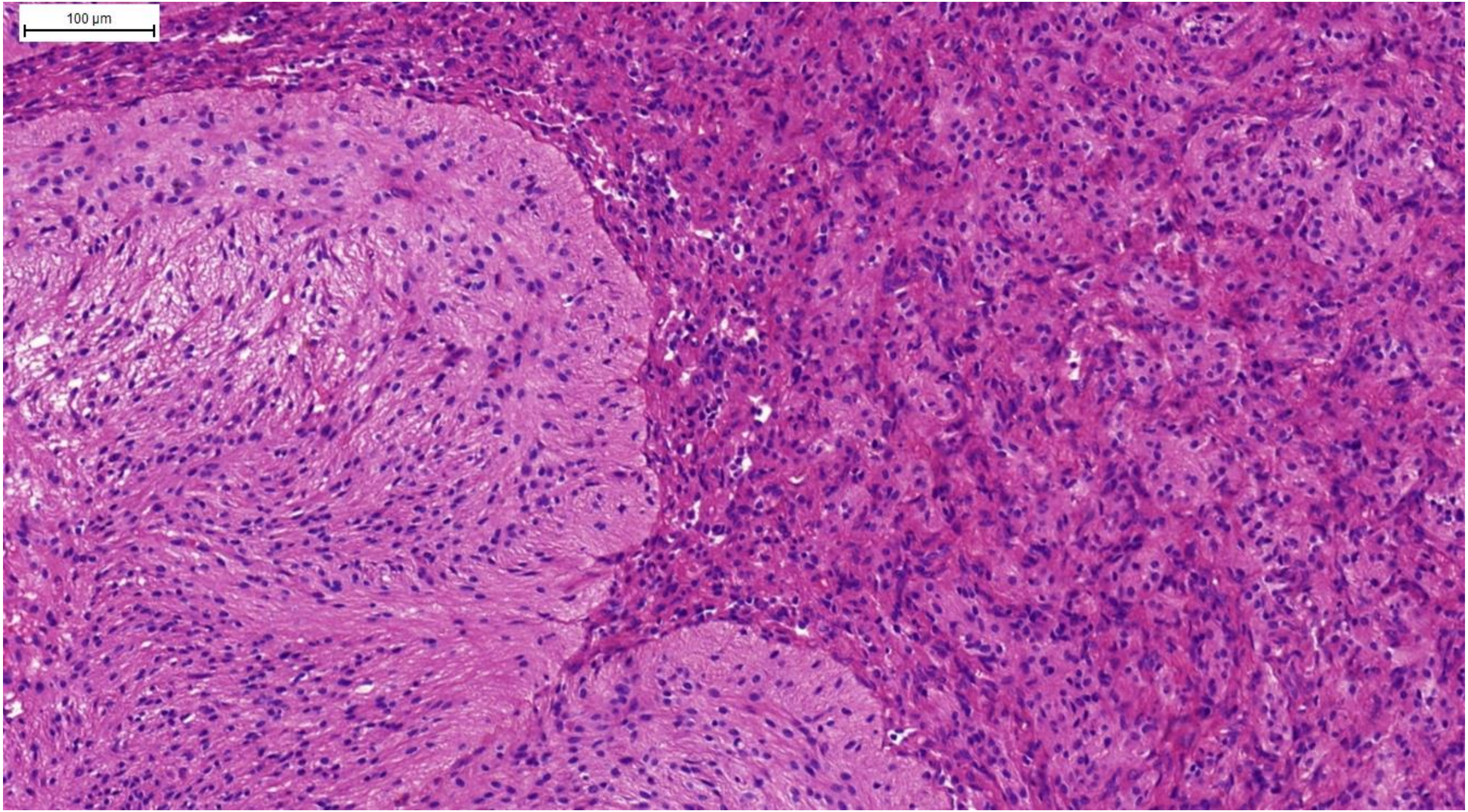
100 µm

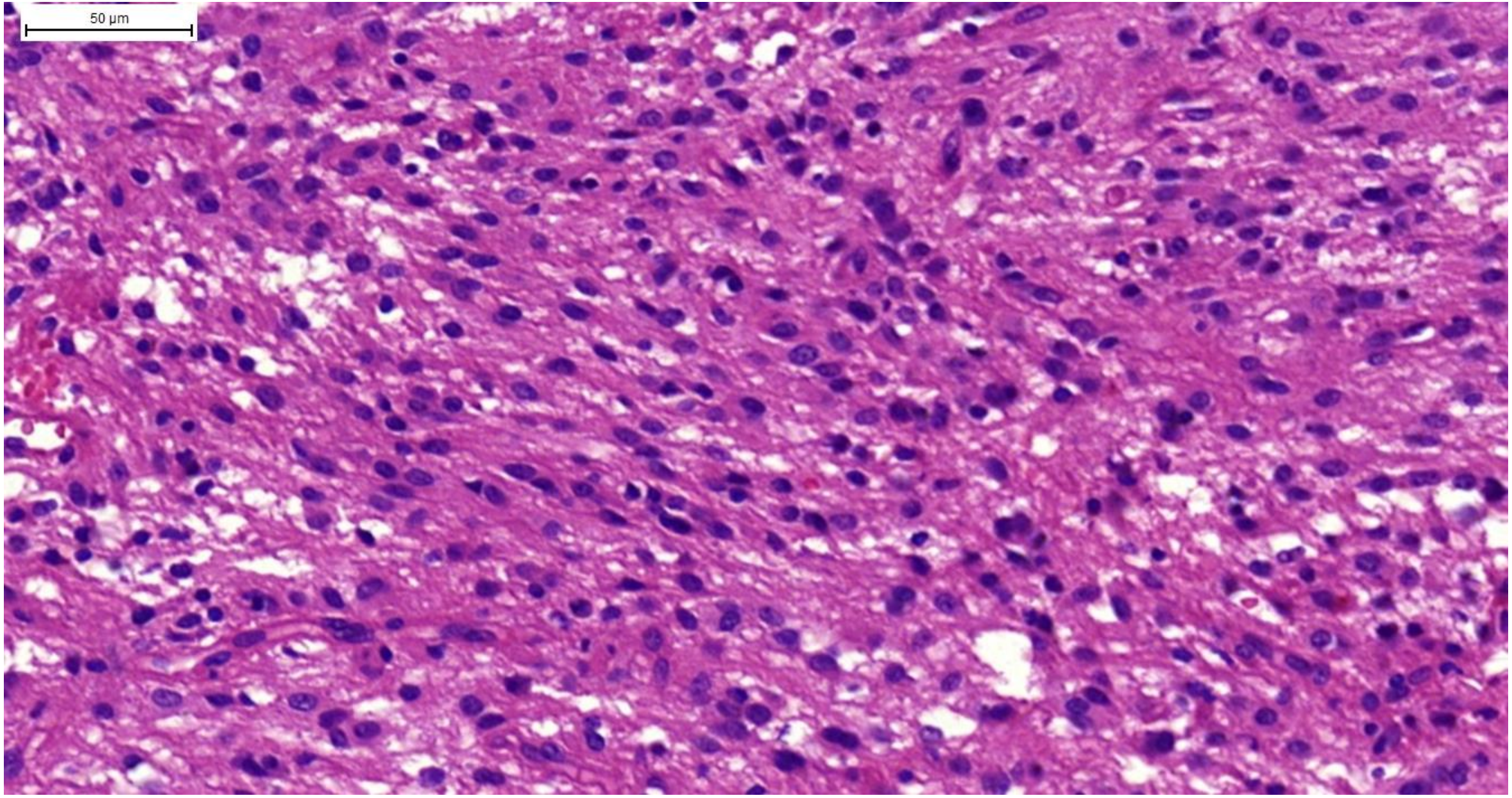
50 µm

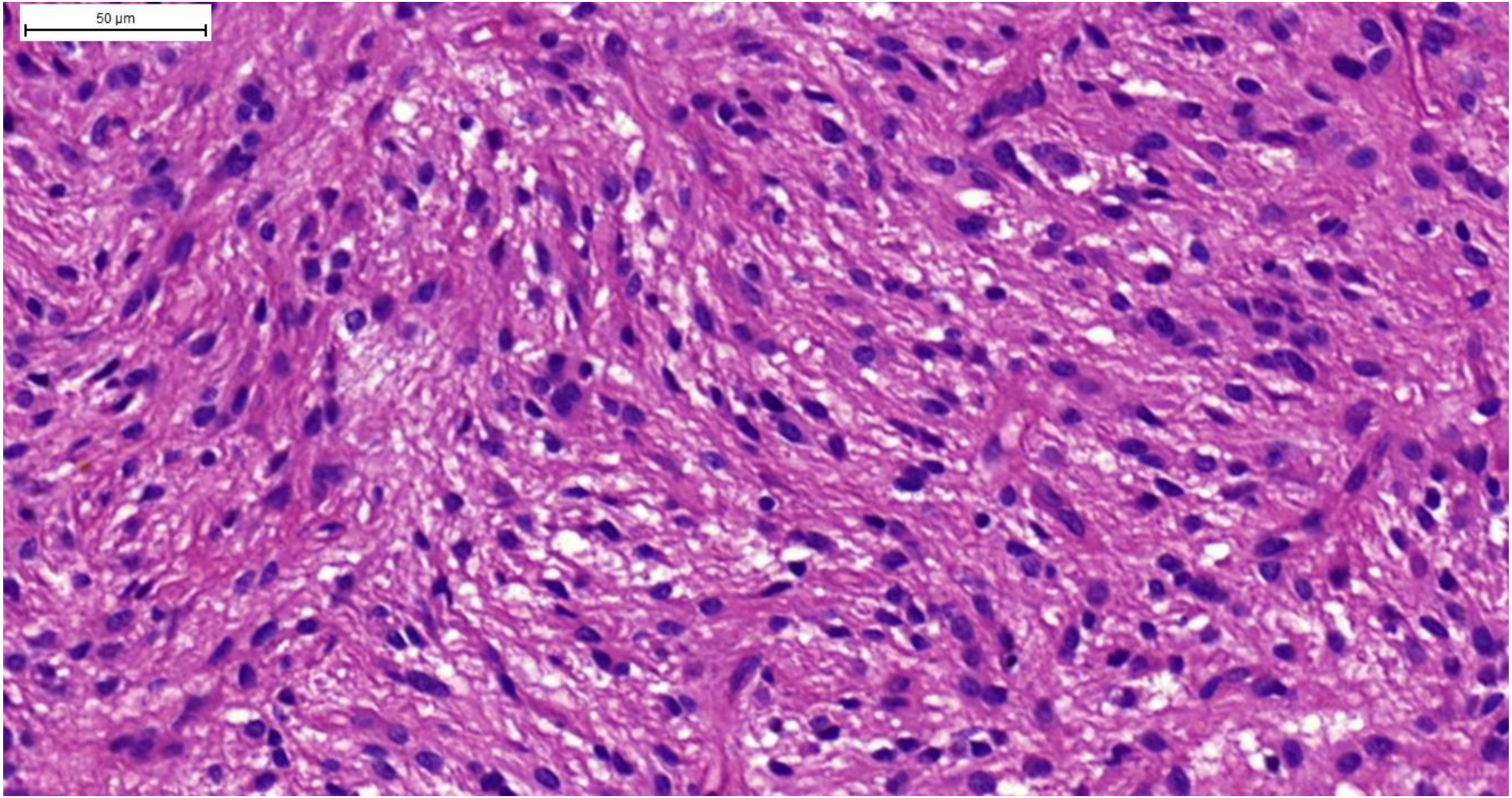
50 µm

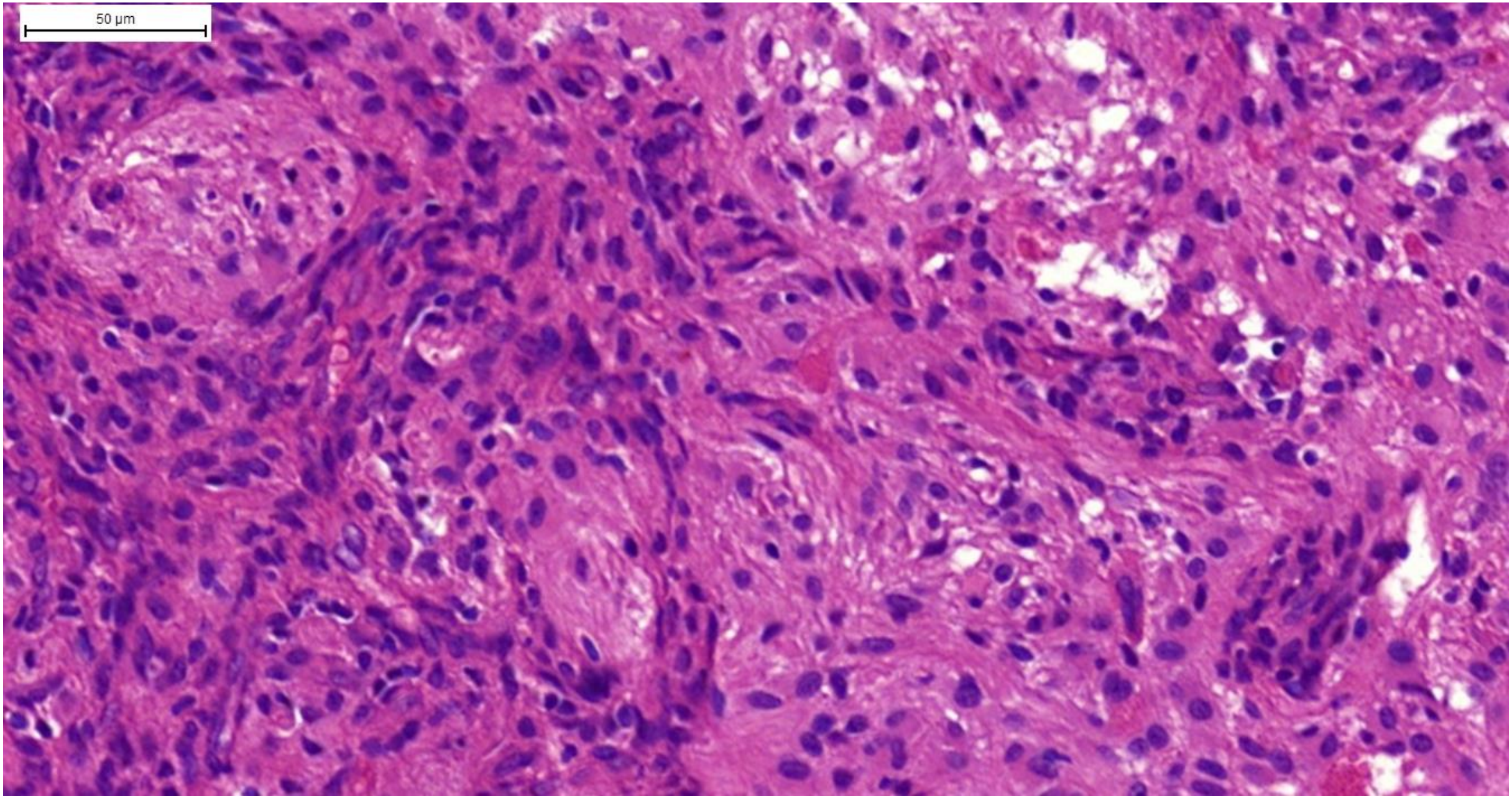
50 µm

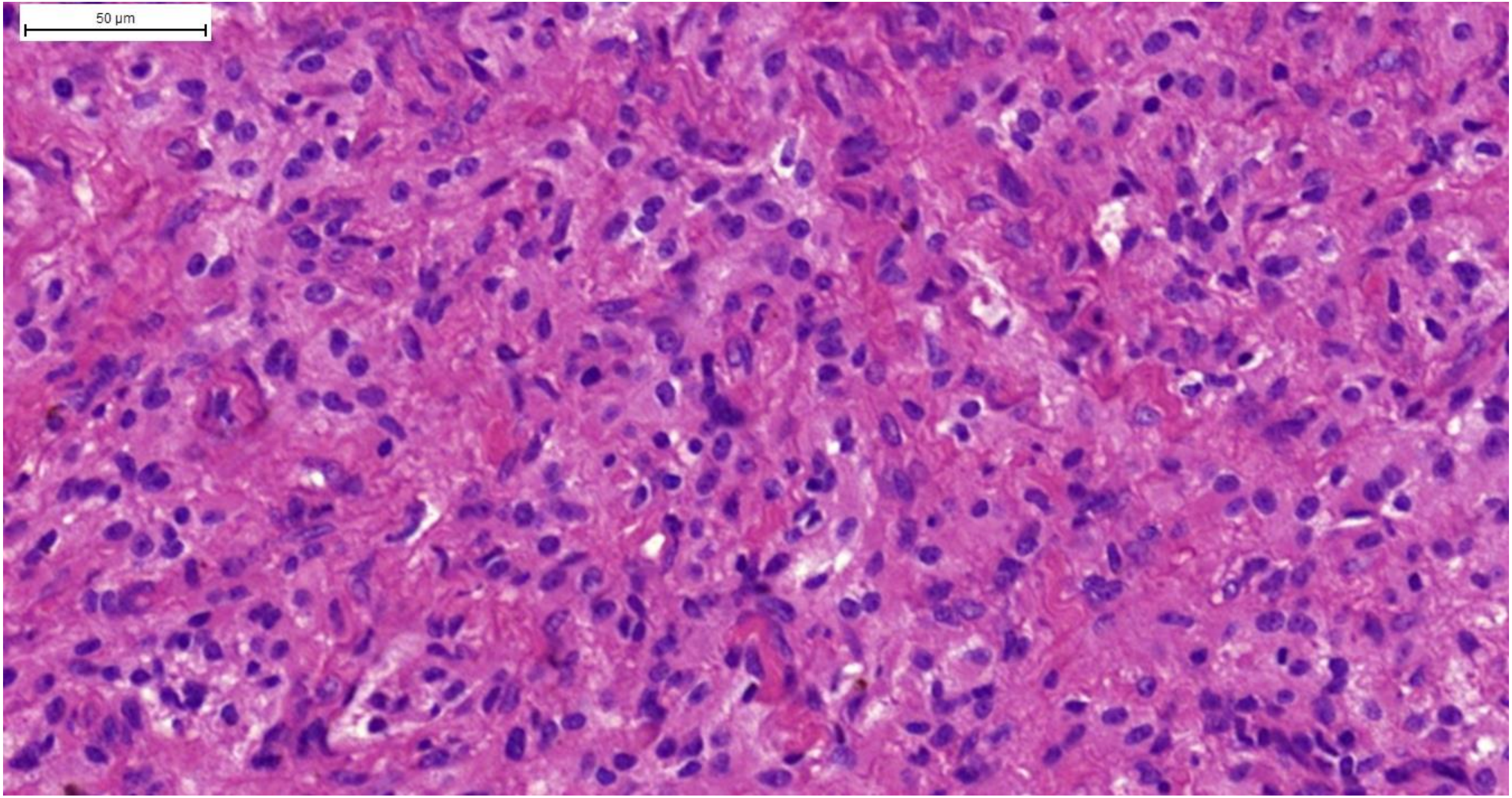
50 µm

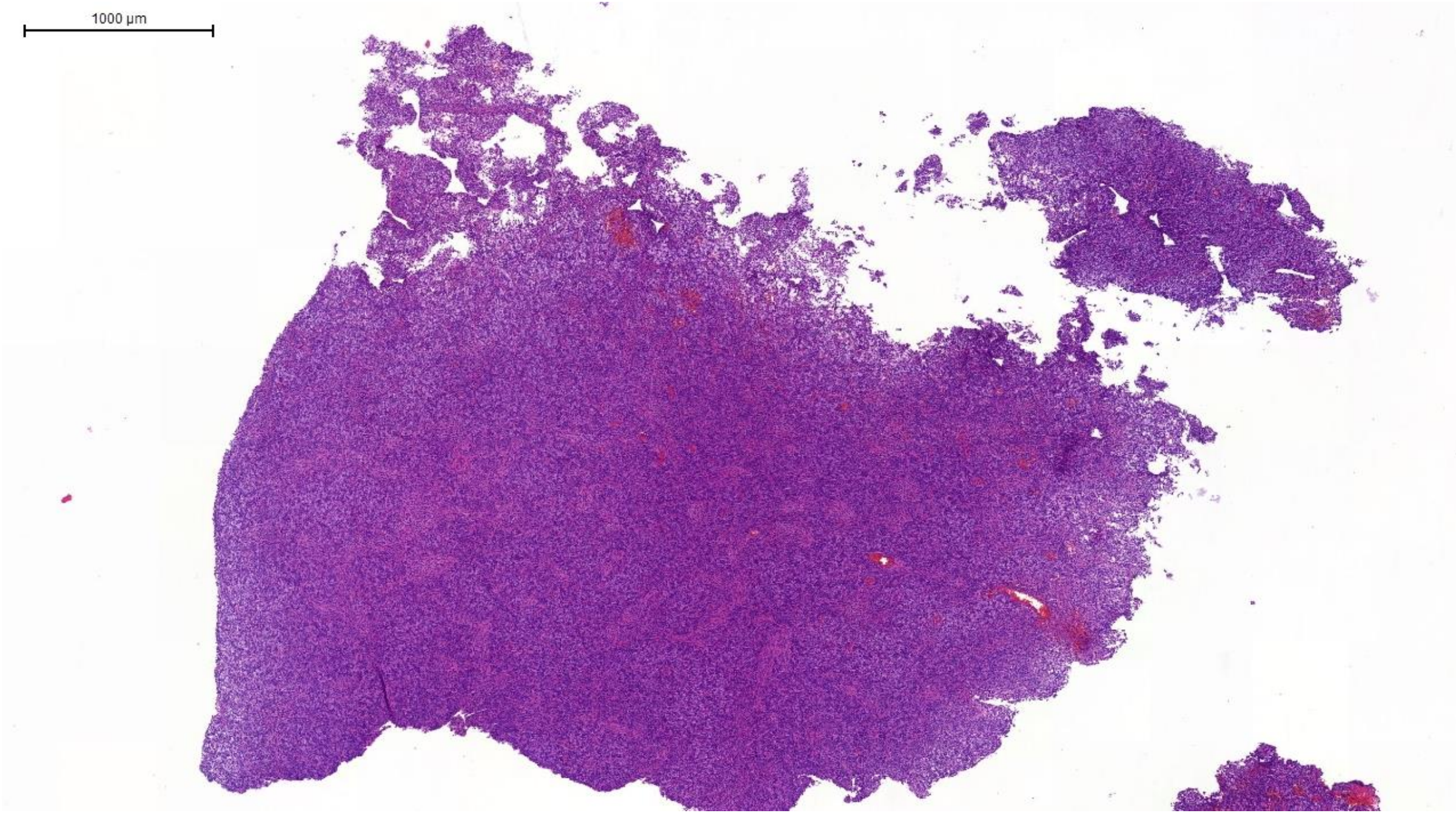
1000 µm

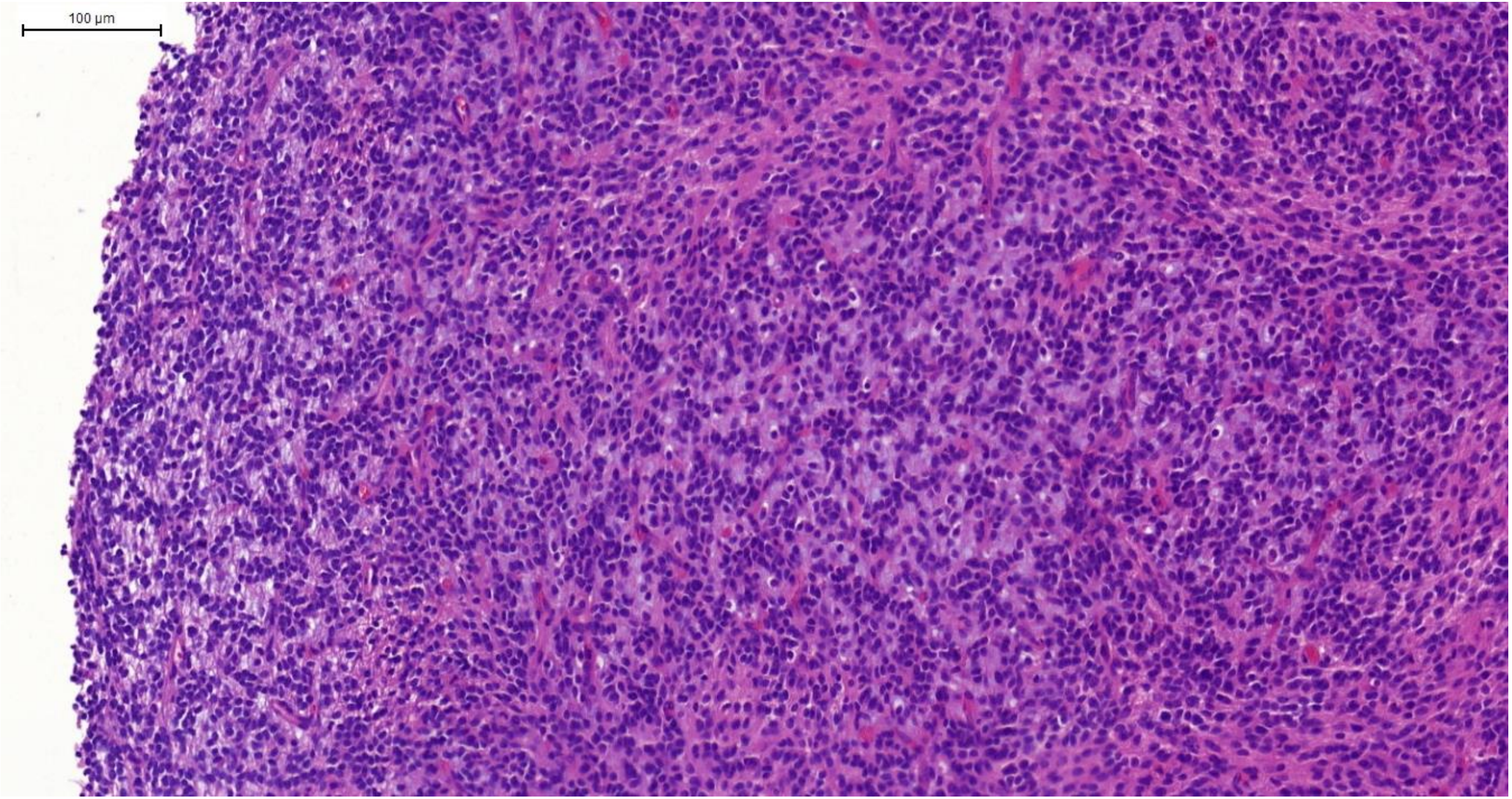
100 µm

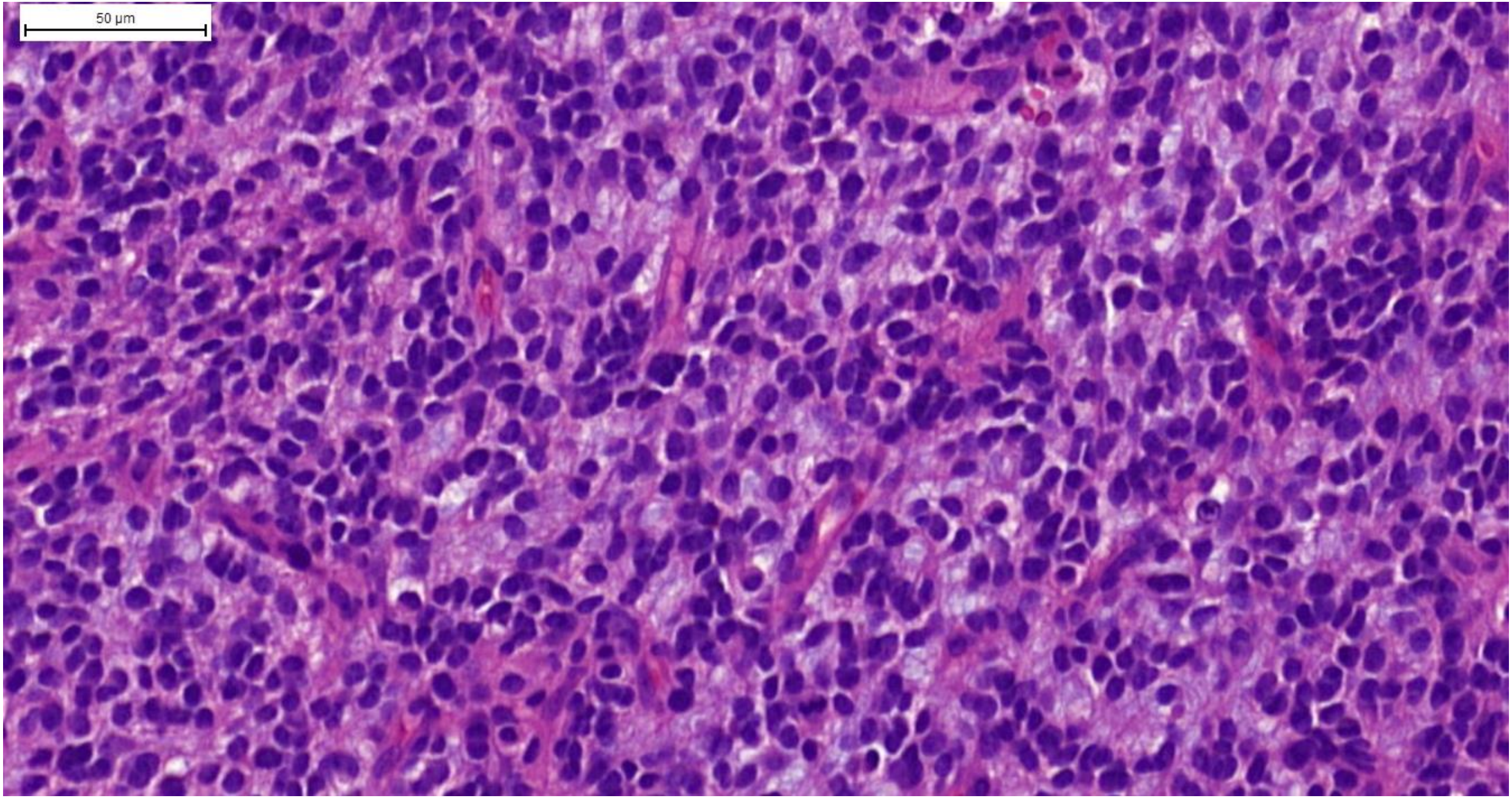
50 µm

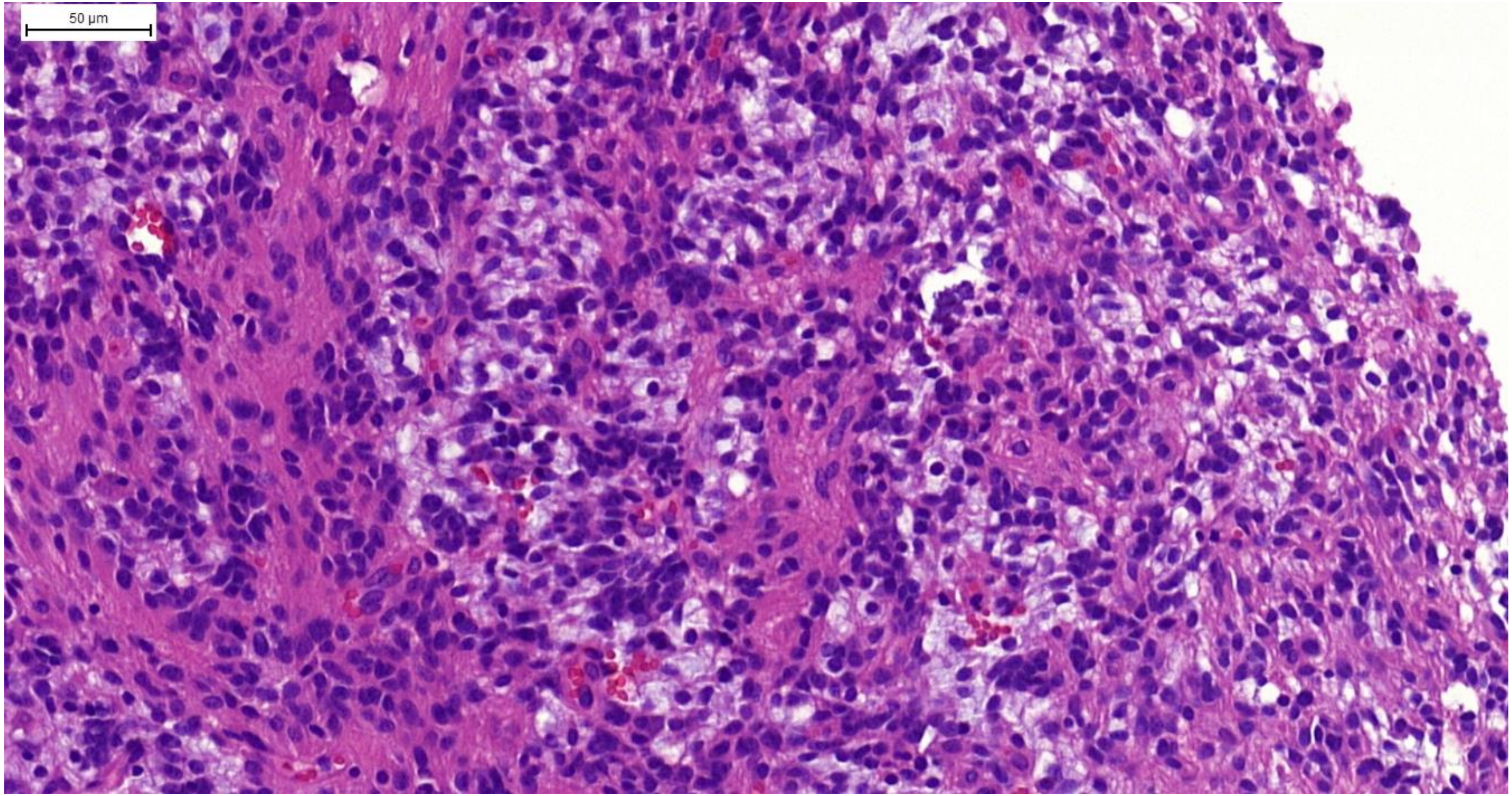
50 µm

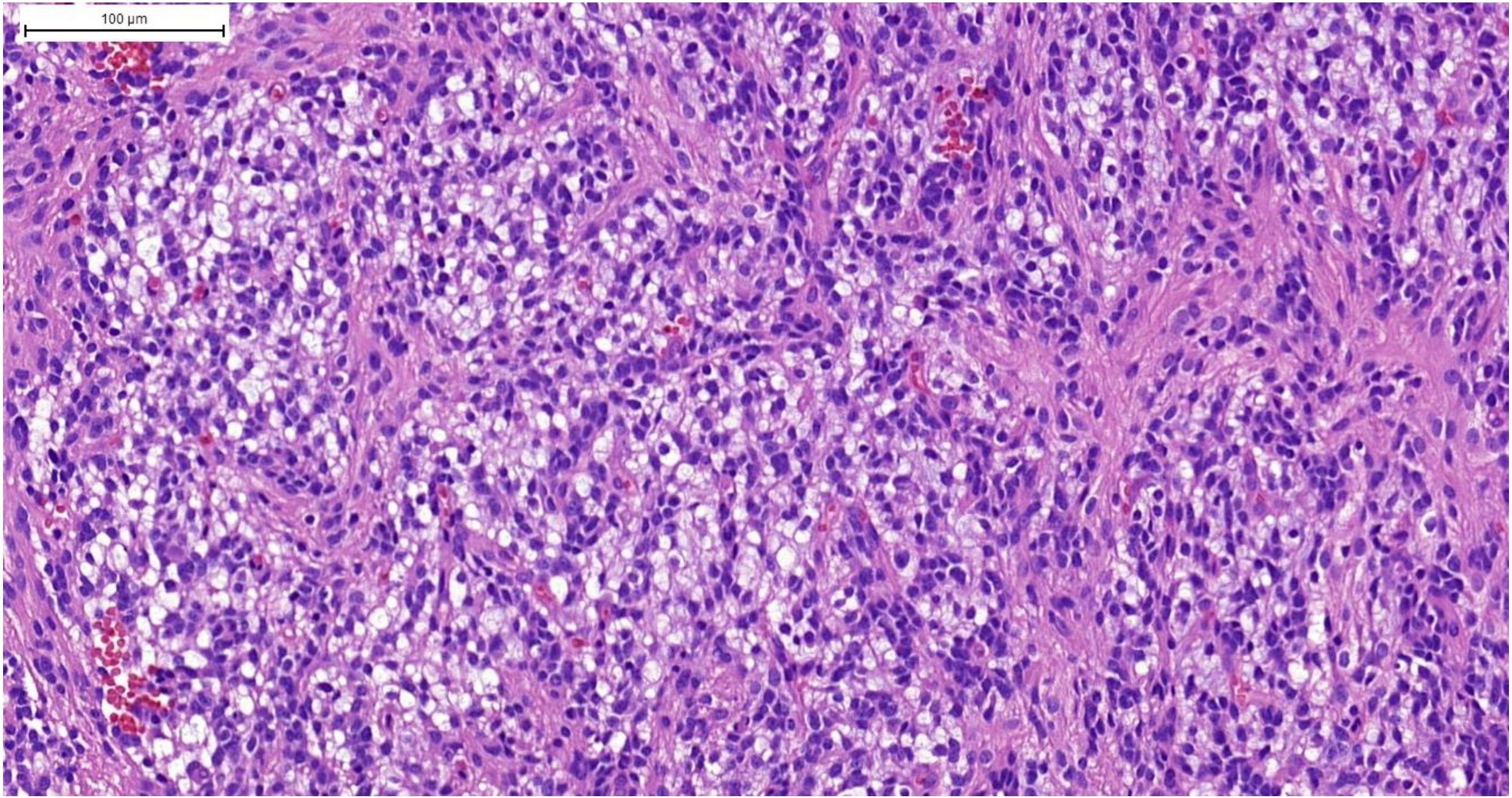
100 µm

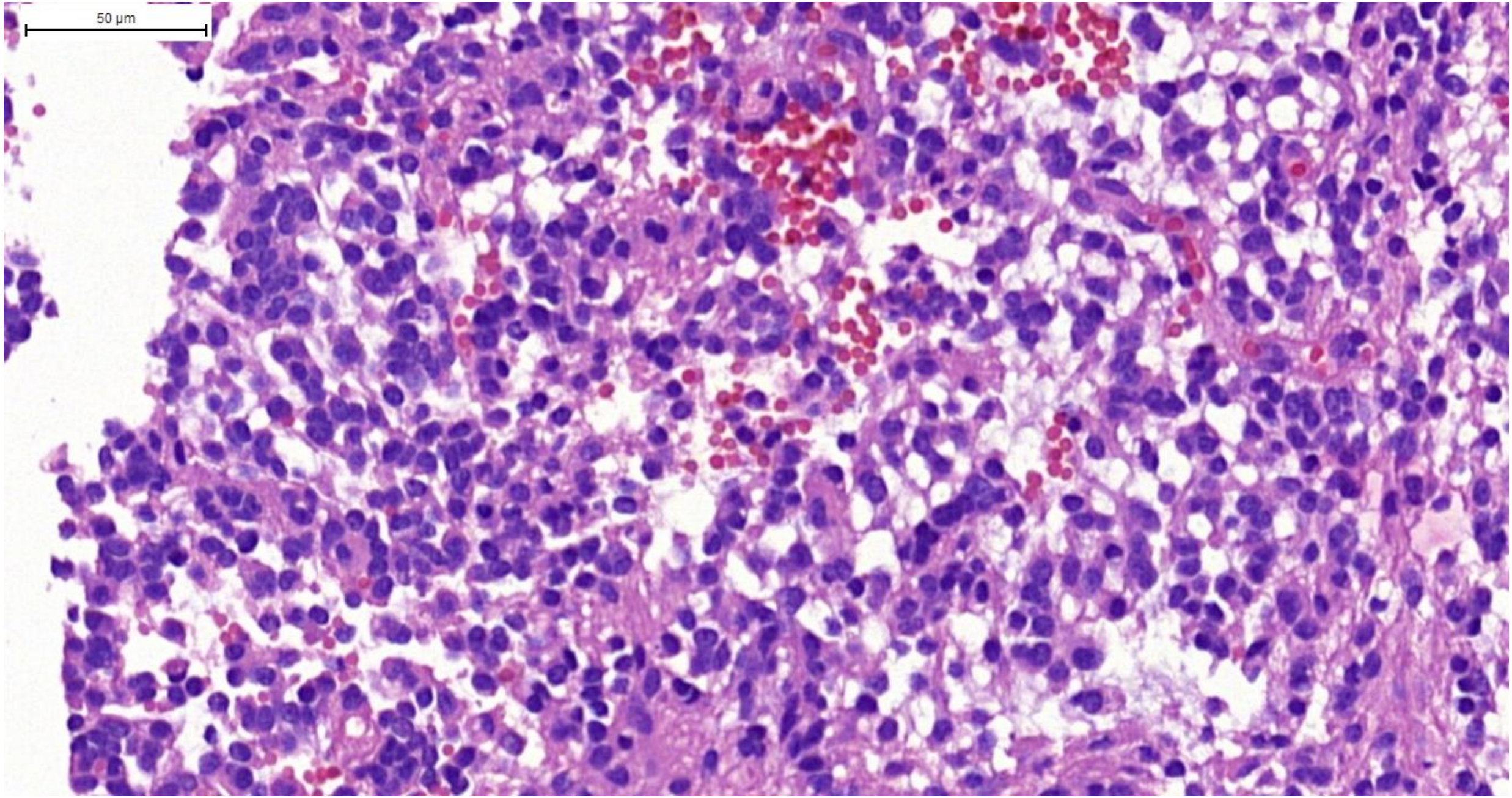
50 µm

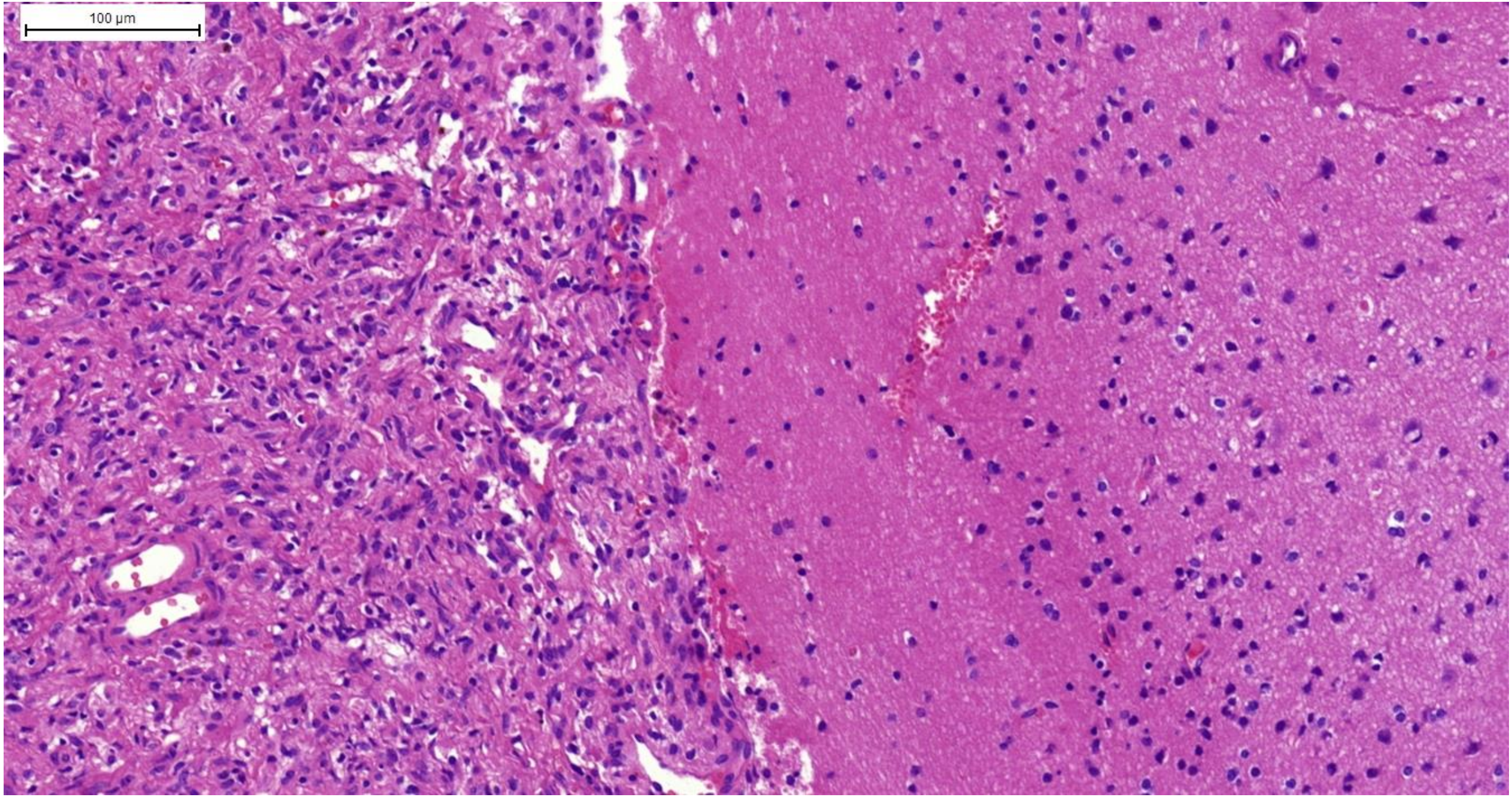
100 µm

?

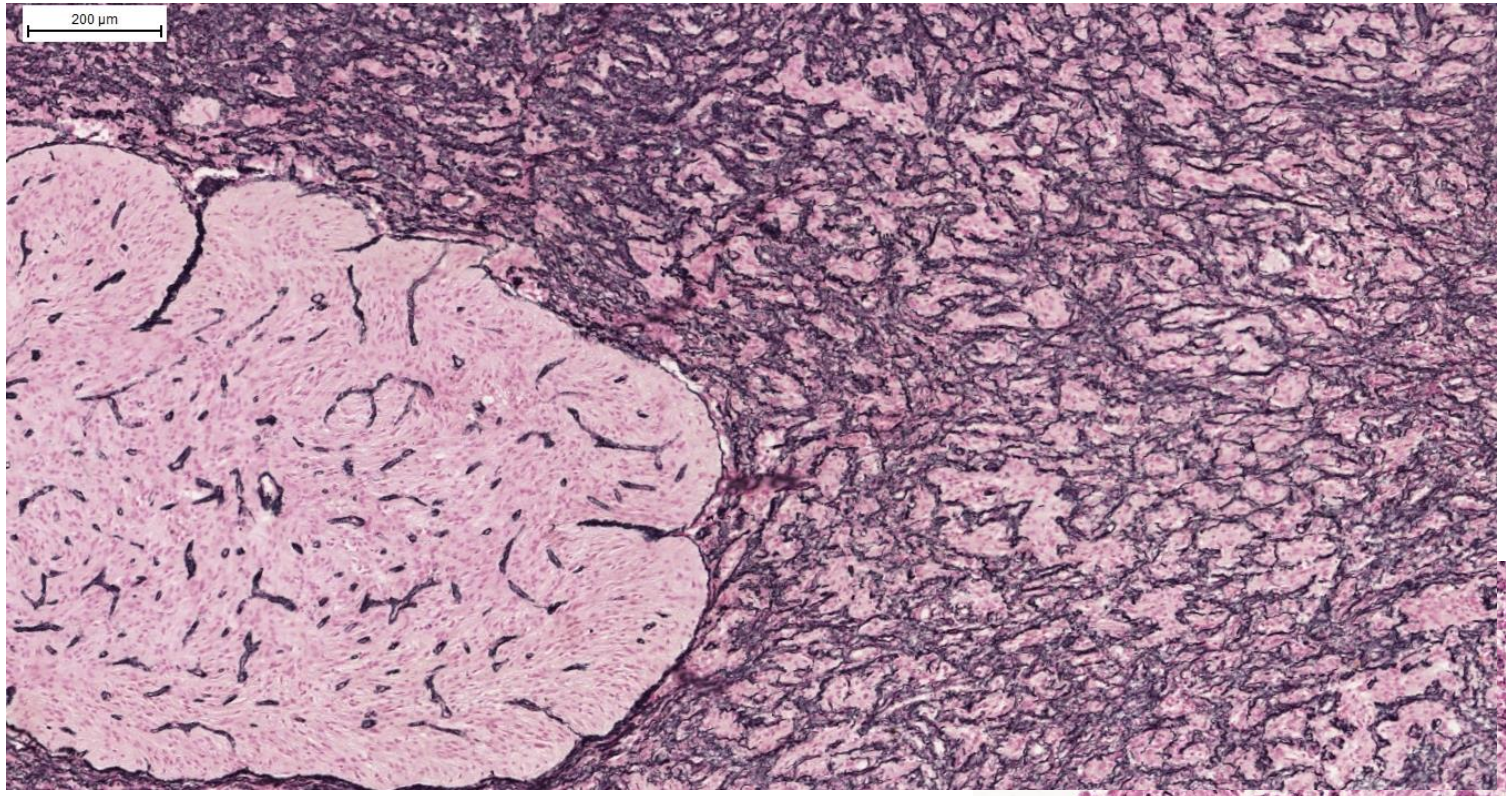

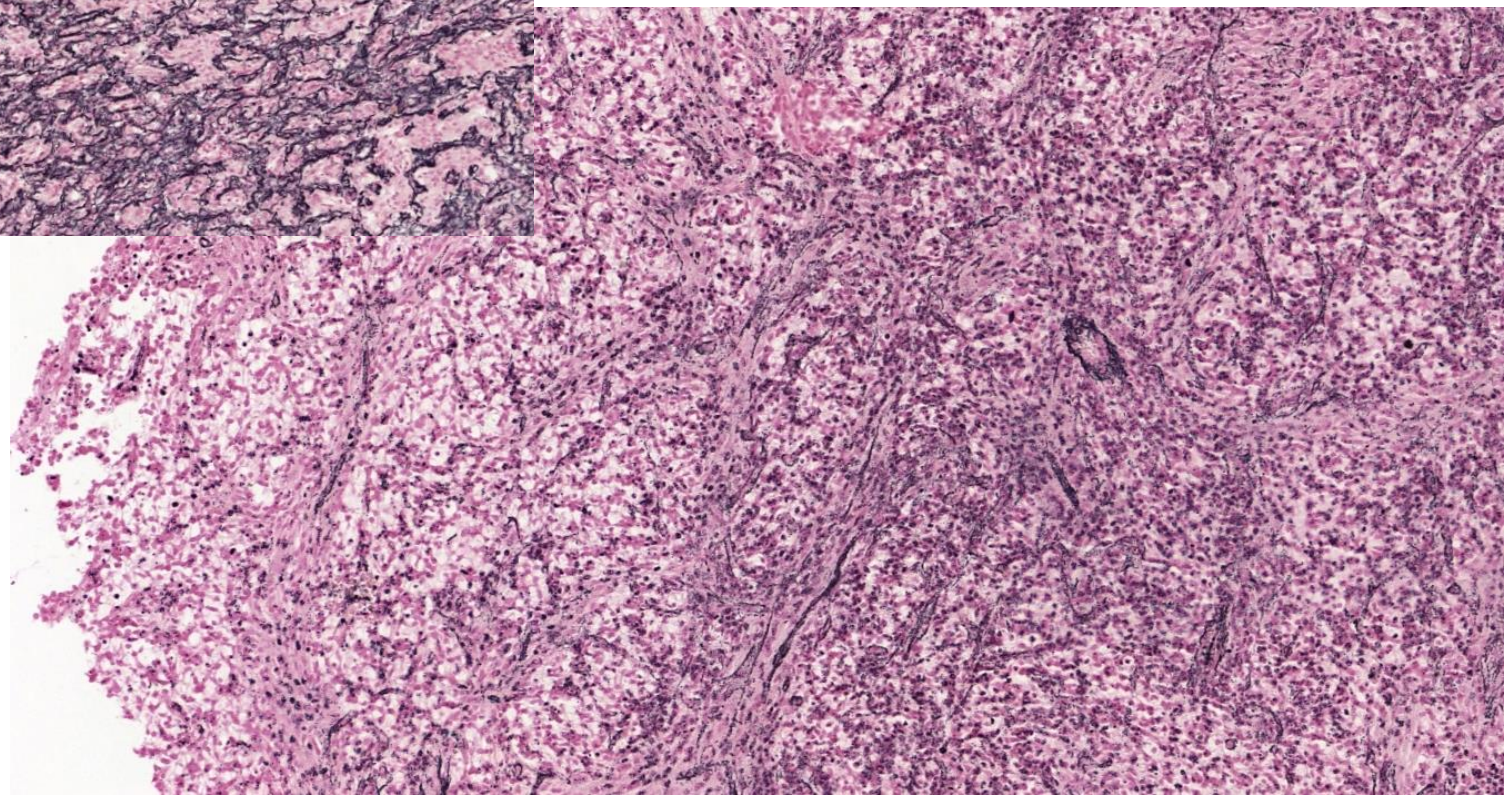

GOMORI

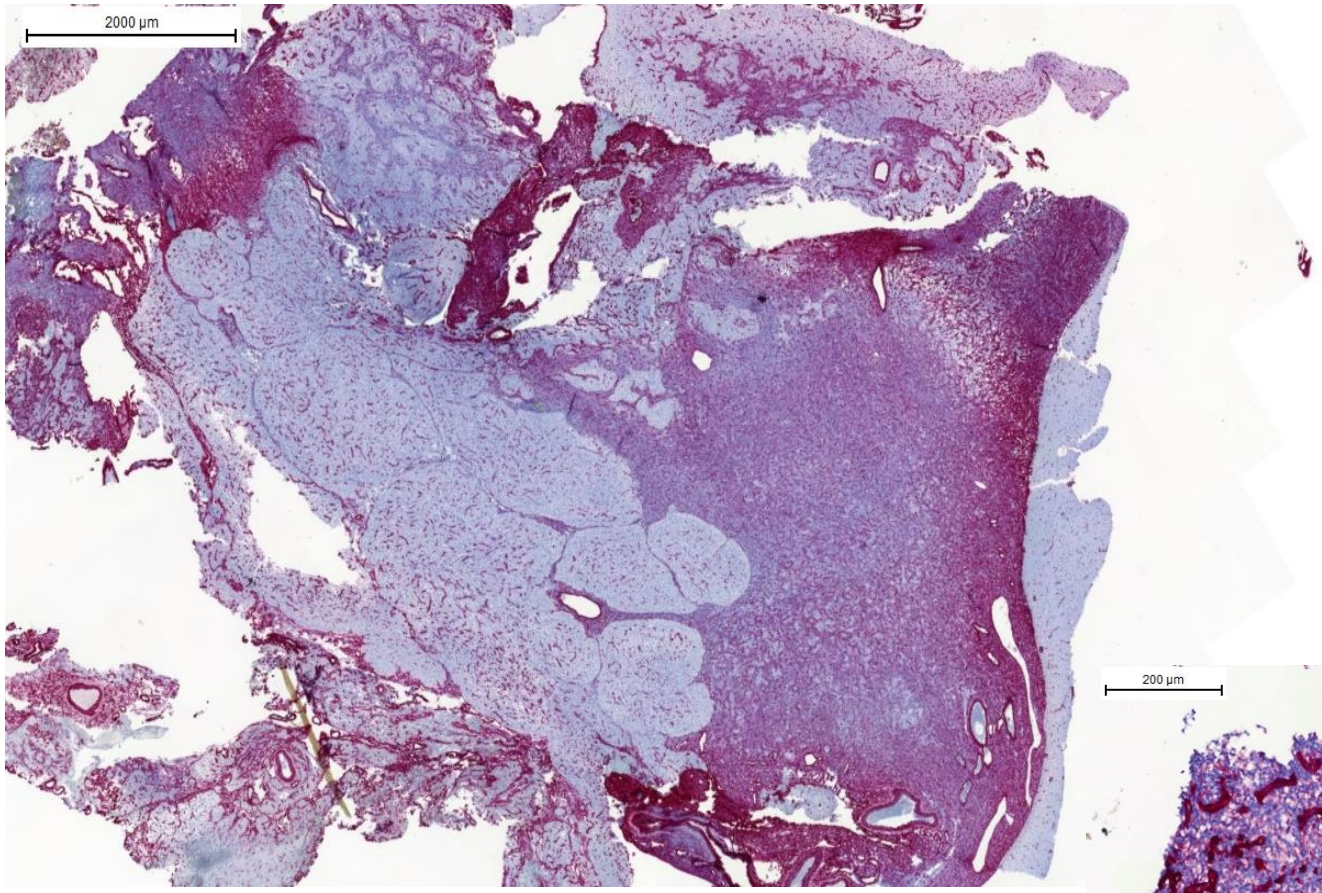

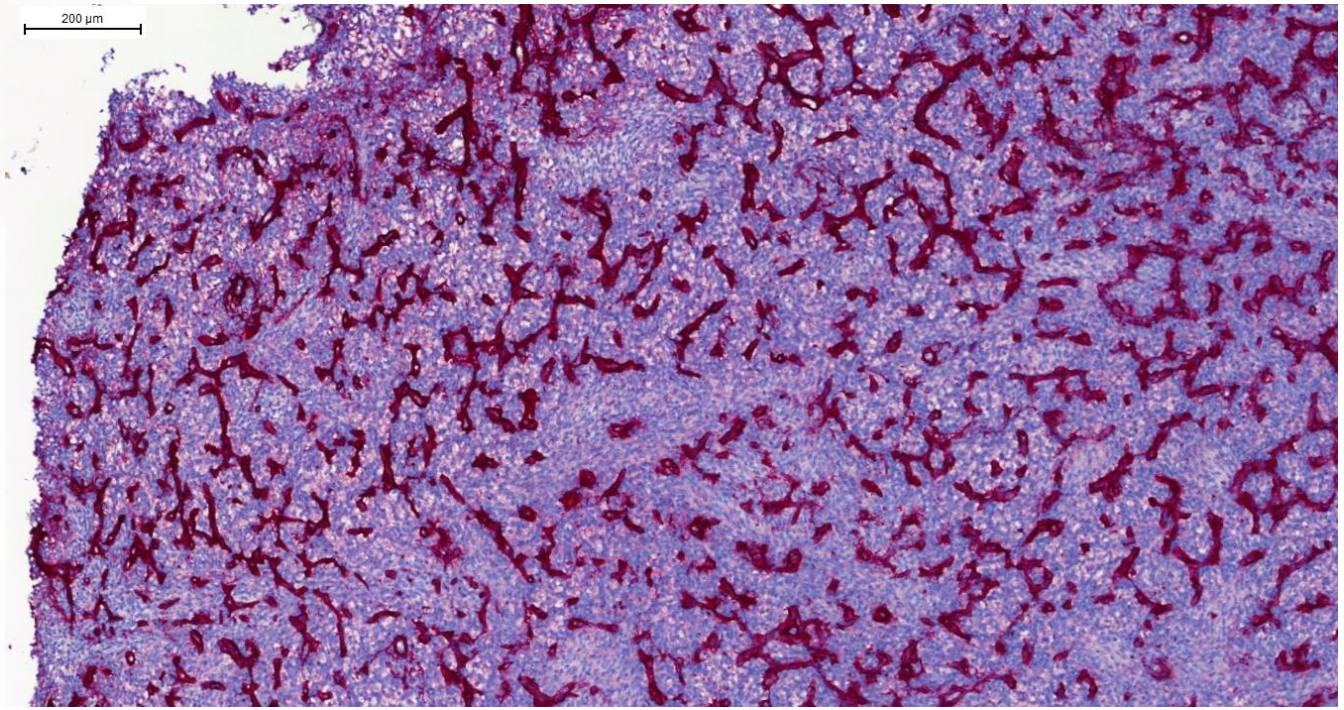

COLLAGEN IV

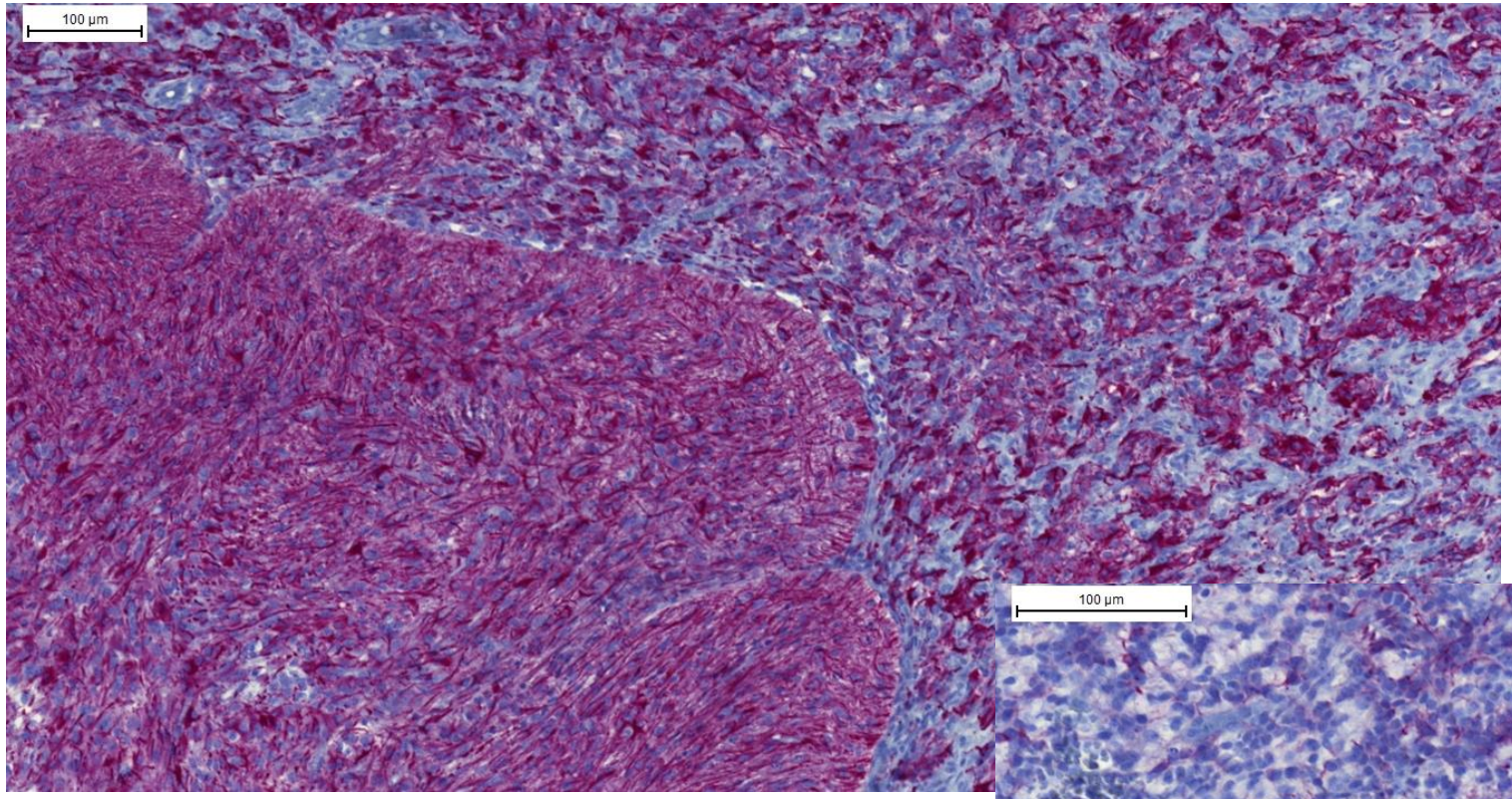

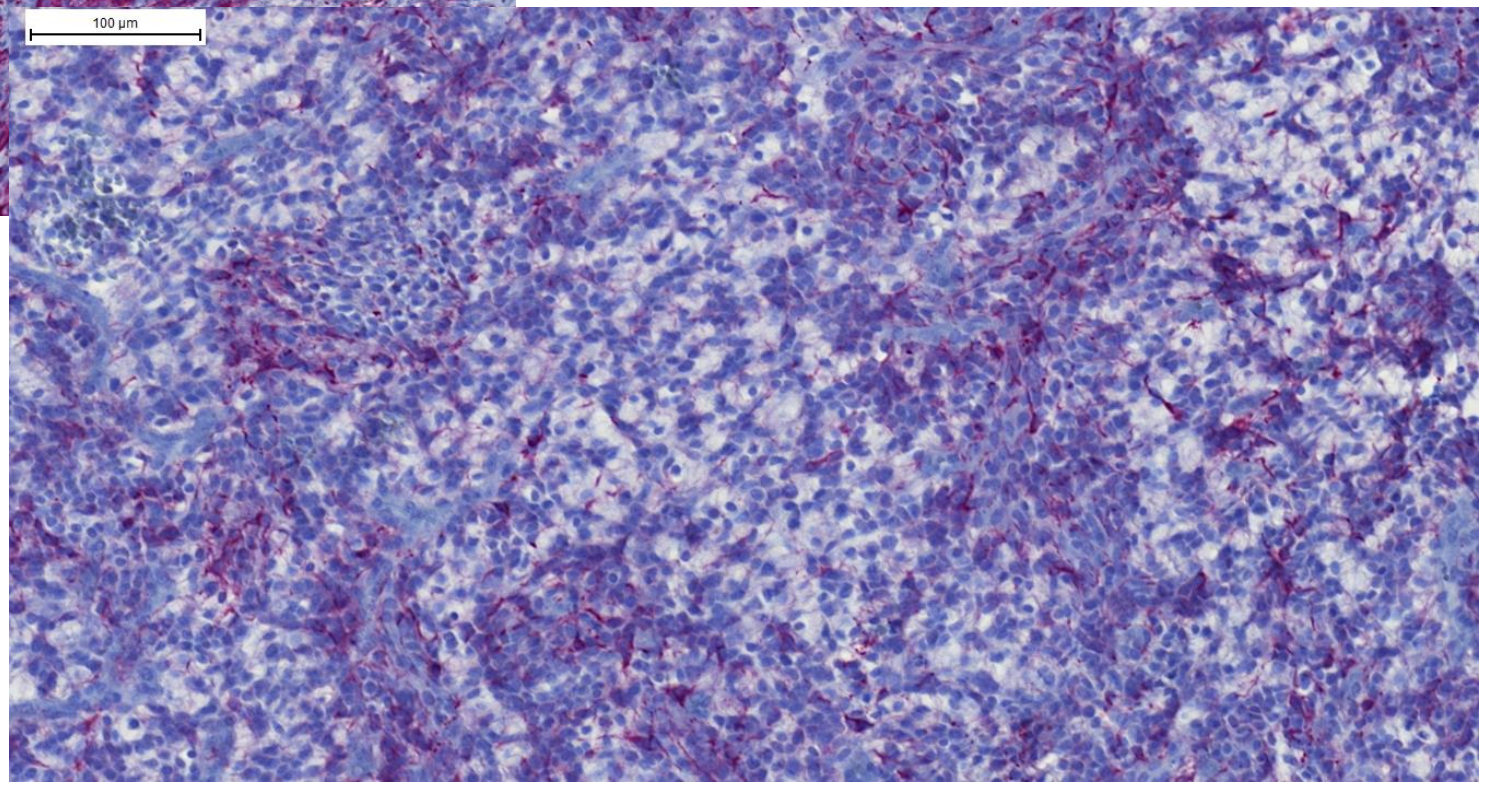

GFAP

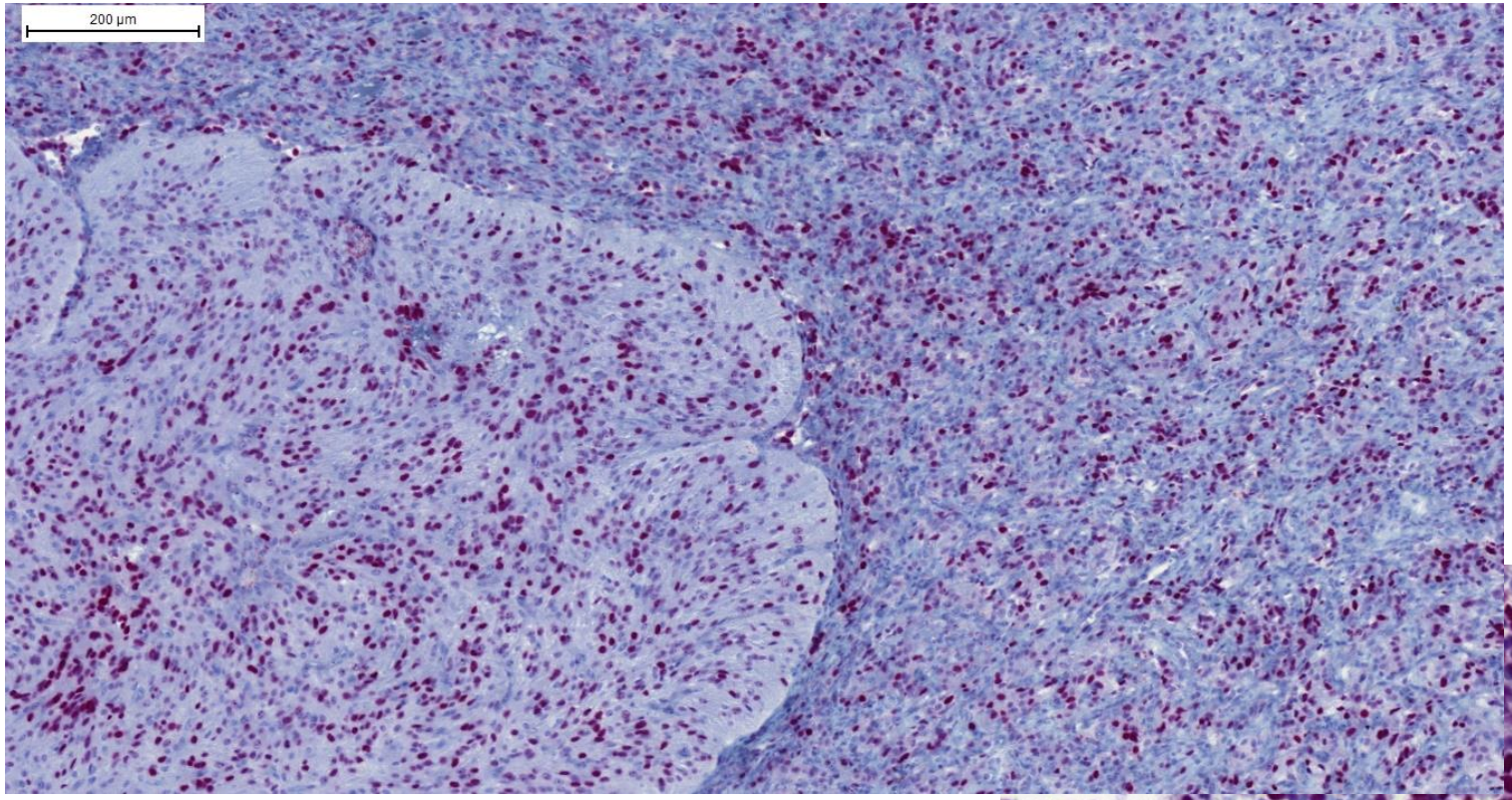

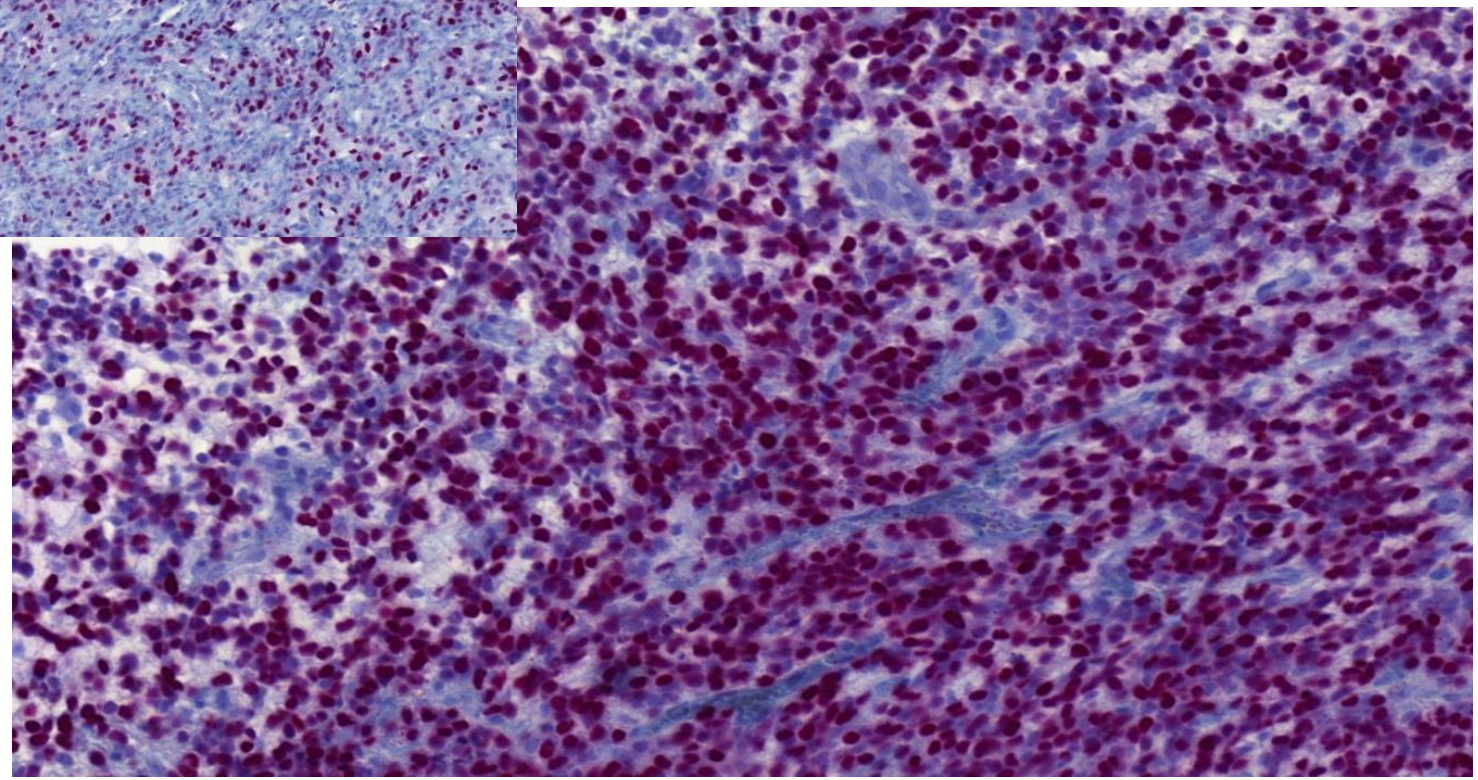

OLIG-2

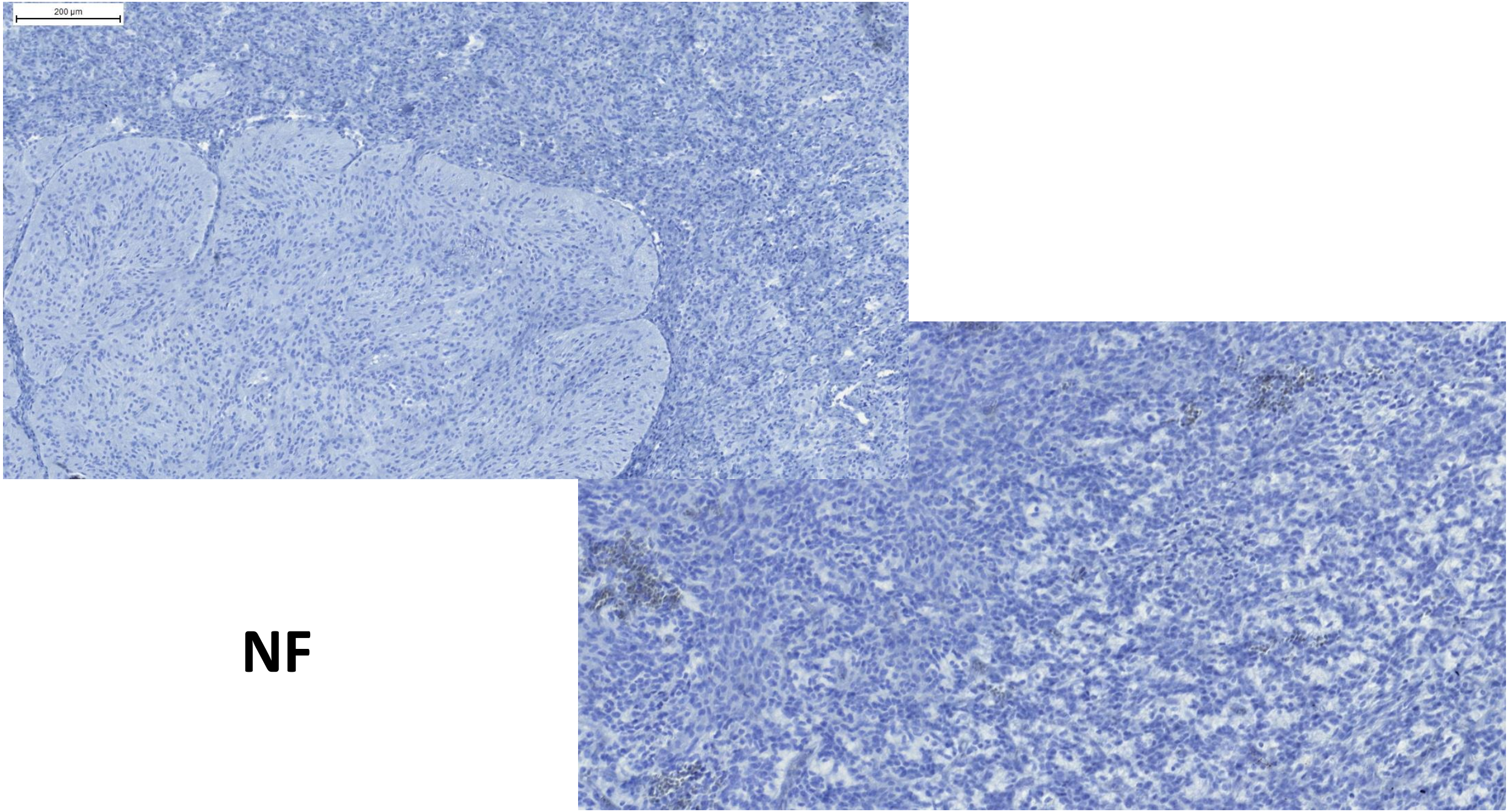

NF

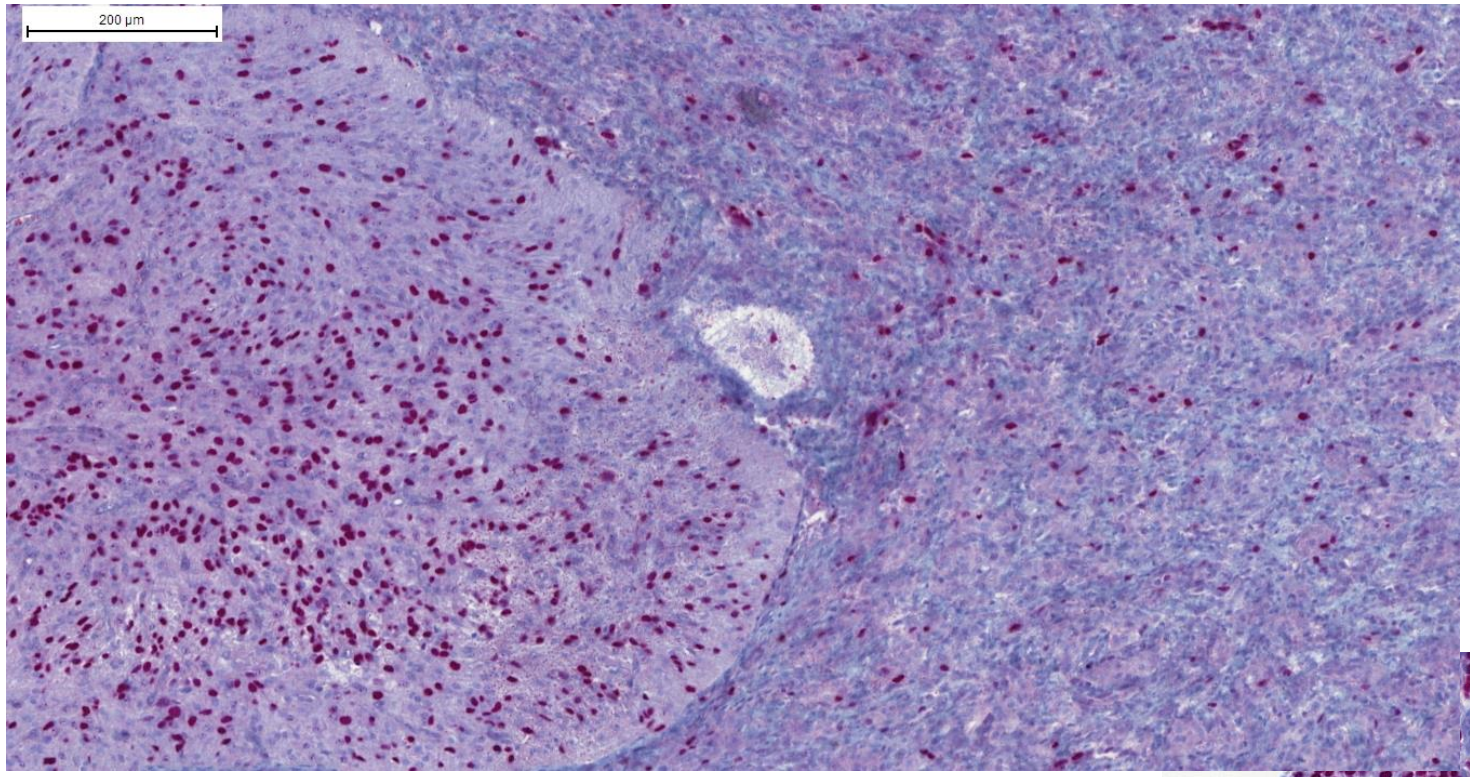

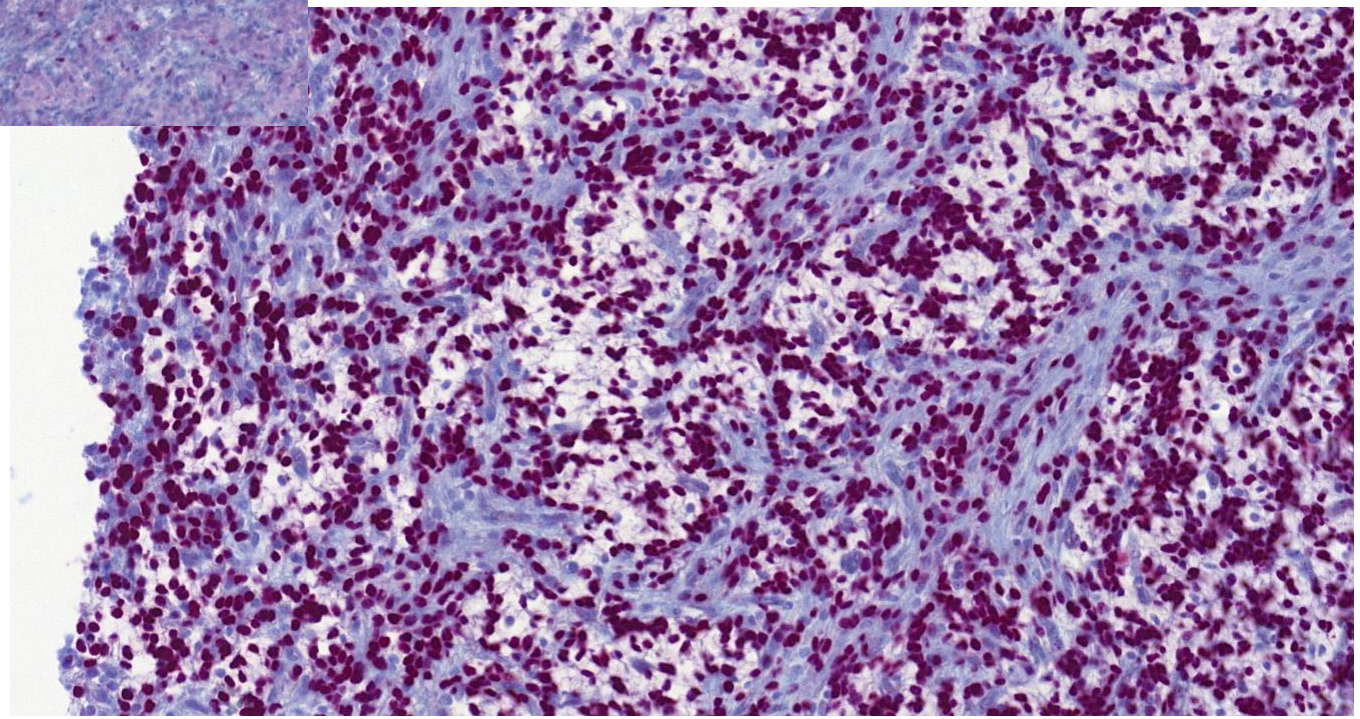

SOX-10

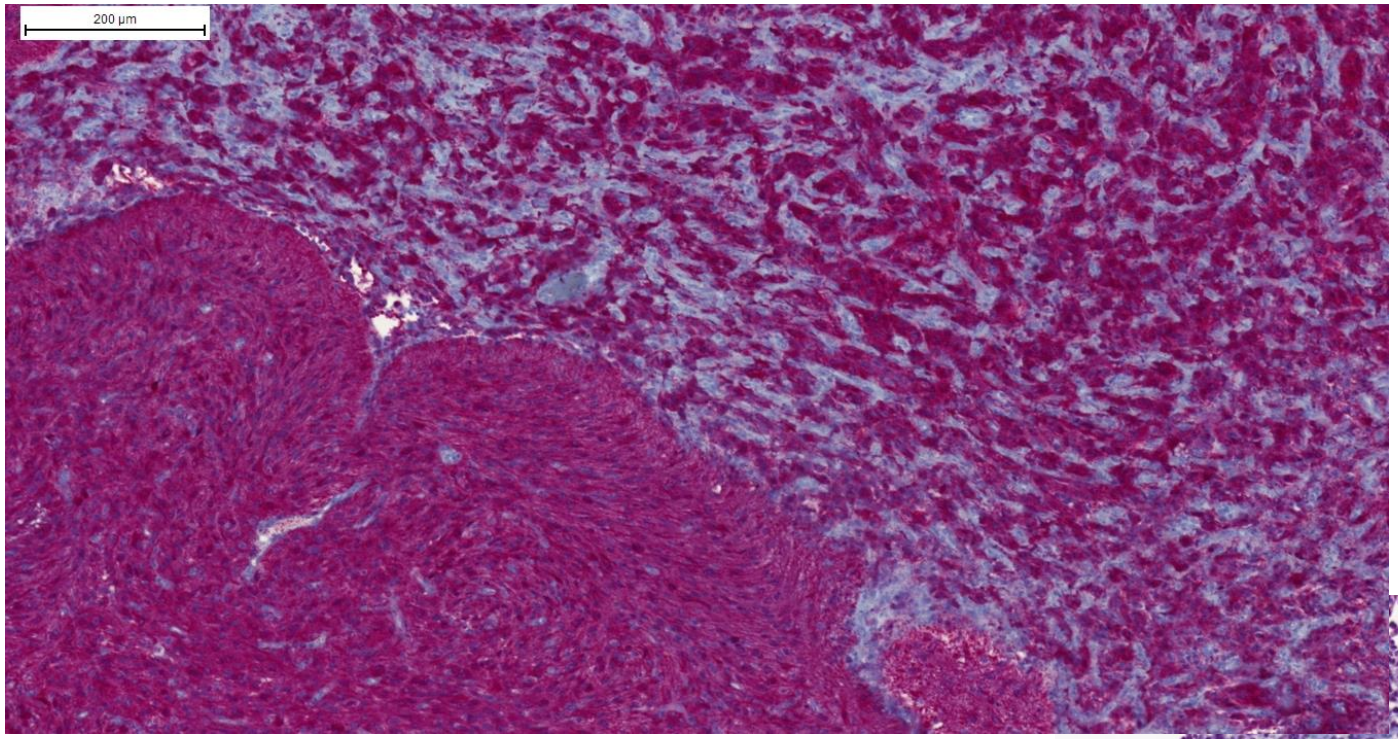

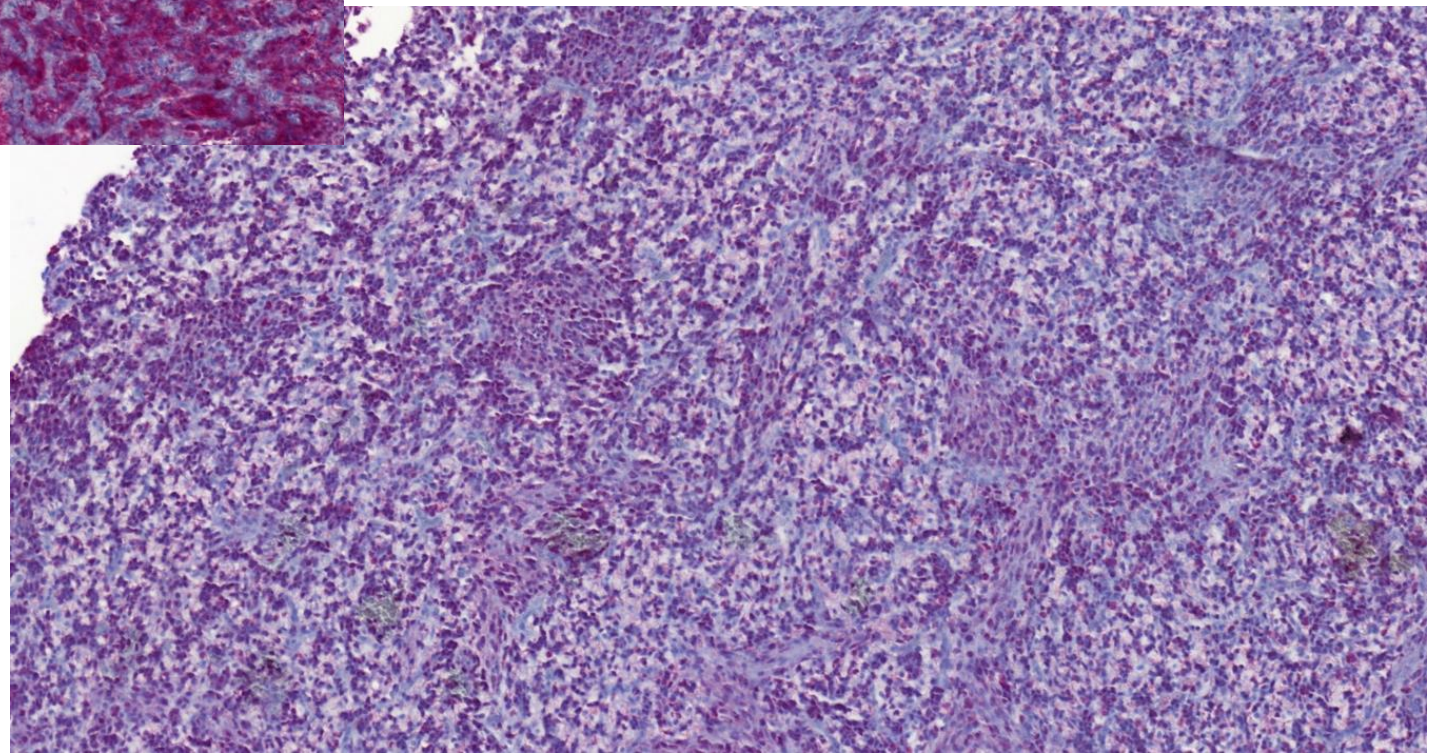

S100

SYNAPTOFYZIN

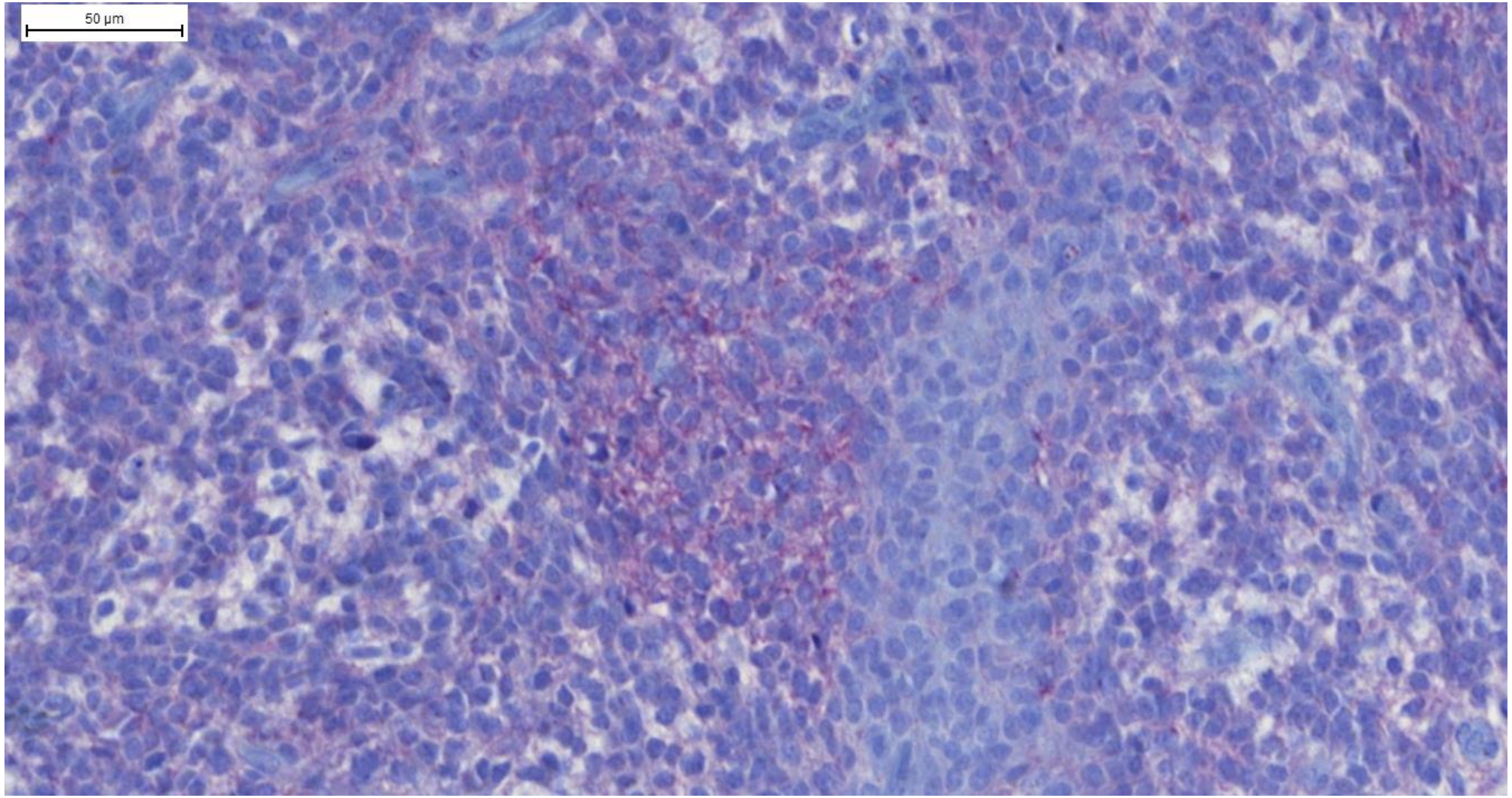

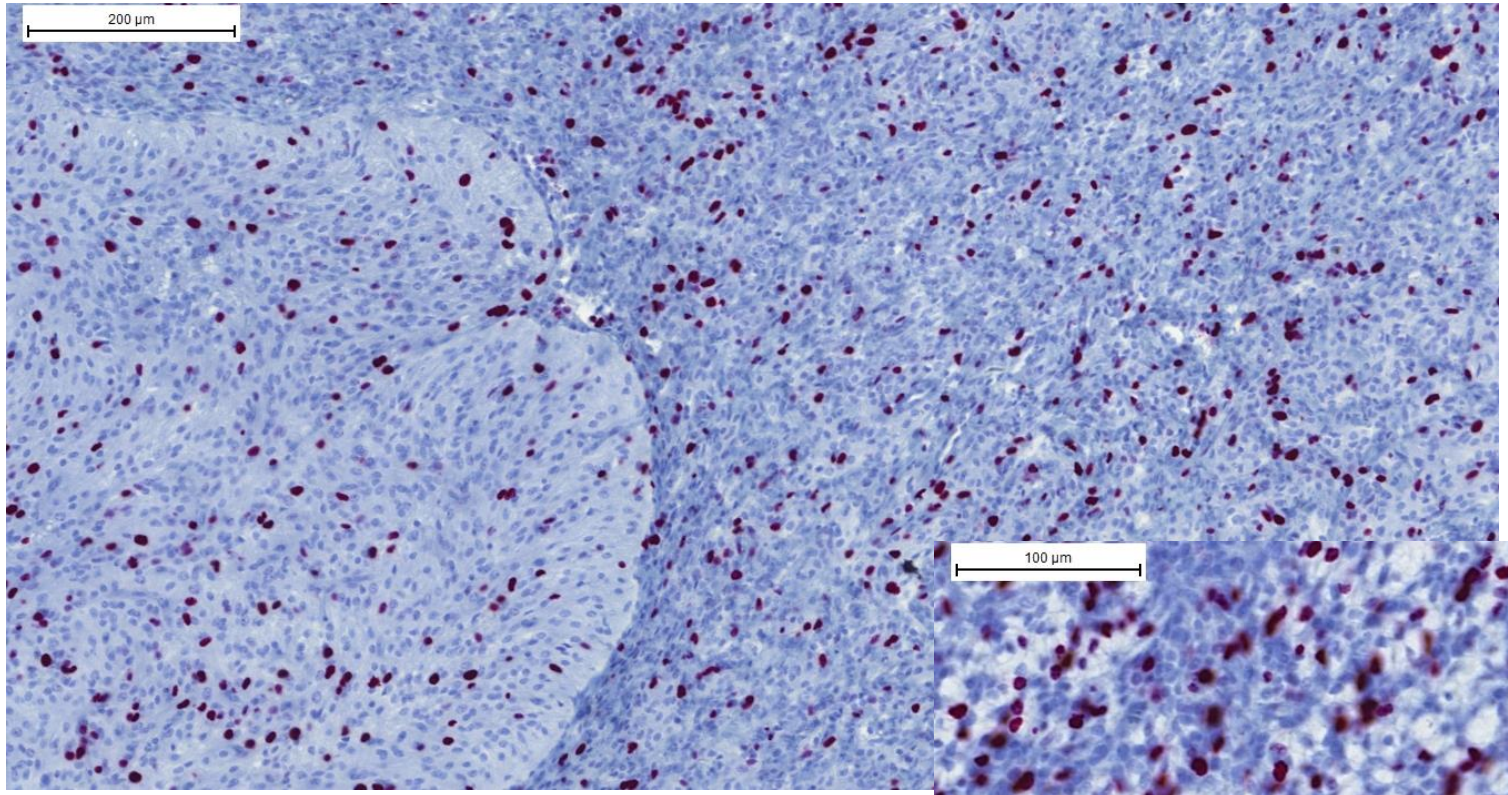

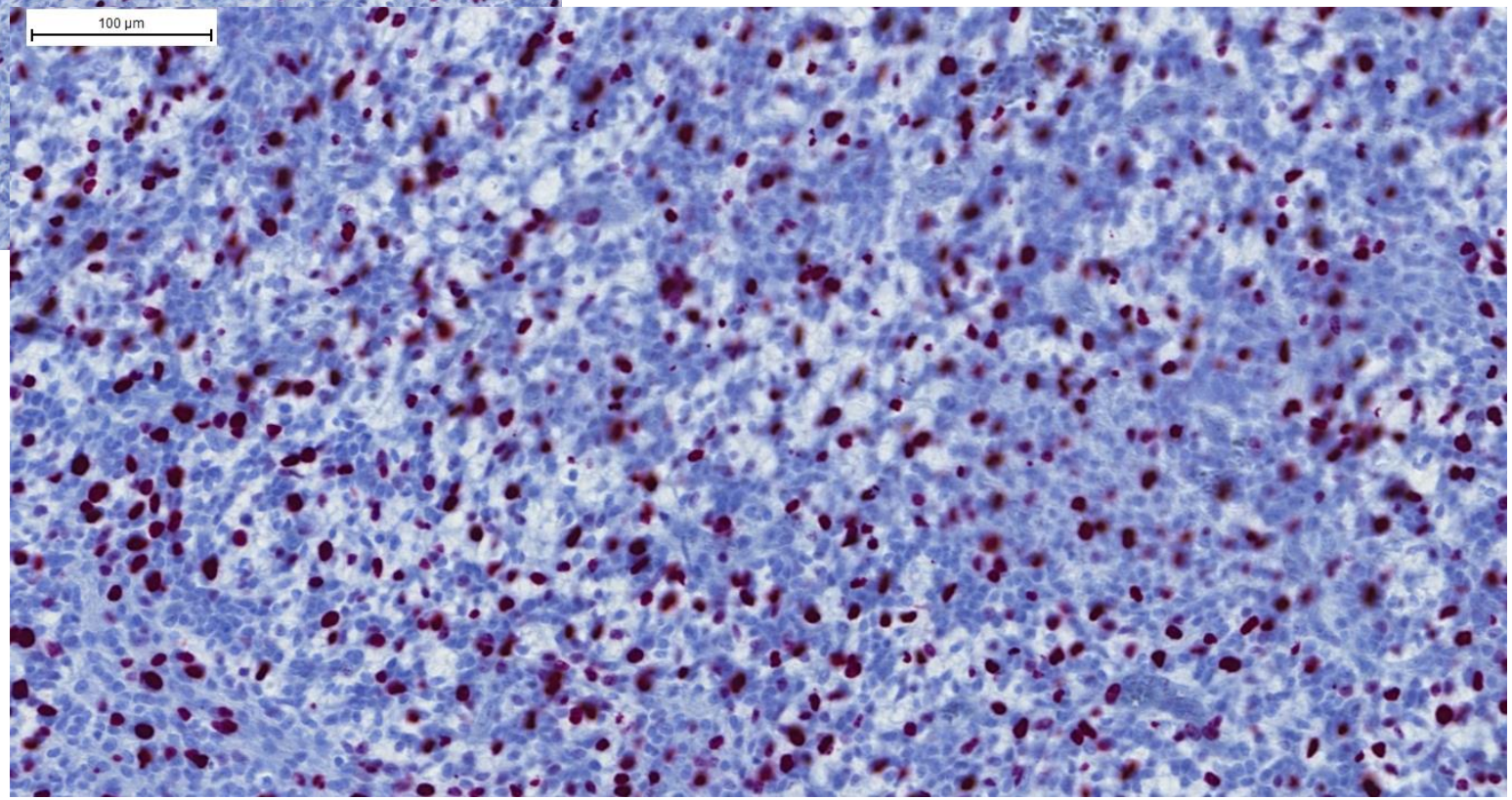

MIB-1

?

DESMOPLASTICKÝ INFANTILNÝ ASTROCYTÓM

WHO grade I

WHO 2016

benígny glioneuronálny tumor tvorený prominentnou desmoplastickou strómou a bunkami neuroepitelu, tvorený:

1) len neoplastickými astrocytmi – ***DESMOPLASTICKÝ INFANTILNÝ ASTROCYTÓM***
2) astrocytmi s variabilne matúrnou neuronálnou komponentou – ***DESMOPLASTICKÝ INFANTILNÝ GANGLIOGLIÓM***

EPIDEMIOLÓGIA

- incidencia **1,25% - 15,8%** zo všetkých pediatrických tumorov mozgu
- M:F = 1,5:1
- väčšina tumorov **prvé 2 roky života** (medián 6 mesiacov)
- sporadické prípady vo veku 5 – 25 rokov (s veľmi silnou predilekciou pre chlapcov)

LOKALITA

- **supratentoriálny kortex a mäkké pleny**
- preferenčne frontálny a parietálny lalok
- častokrát postihnutie viacerých lalokov
- **častokrát fixované ku tvrdej plene**

MIKRO

- Desmoplastická komponenta

1) Fibroblastycké vretenovité bunky – tvorba retikulínu a kolagénu
2) Hojné kolagénové väzivo
3) Mierne pleomorfné neoplastické astrocyty
   - DIA – len astrocyty
   - DIG – astrocyty + gangliové bunky

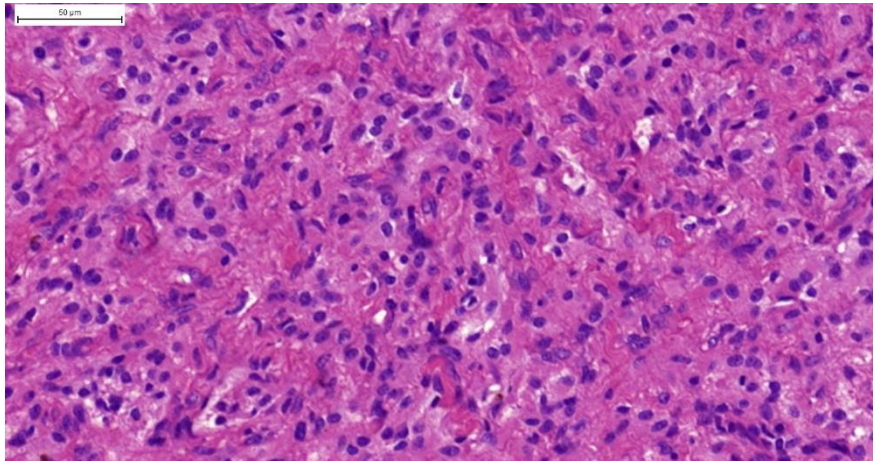

MIKRO

- Imatúrna komponenta bez desmoplázie
  - nízko diferencované neuroepitelové bunky s malými okrúhlymi bazofilnými jadrami s minimálnou cytoplazmou
  - môžu fokálne prevažovať

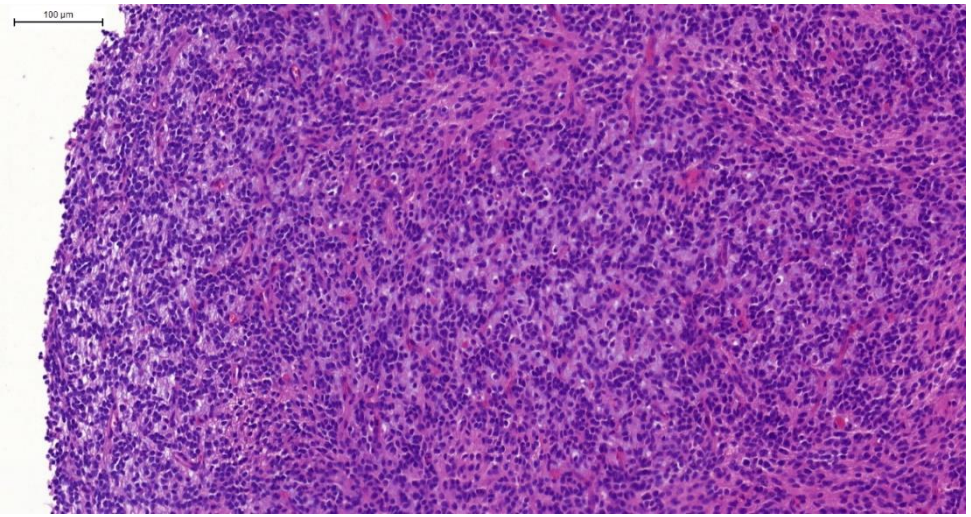

MIKRO

- ostré ohraničenie medzi tumorom a okolím
- bežné sú kalcifikácie
- zriedkavé nekrózy (väčšinou len v nízko diferencovanej neuroepitelovej komponente)
- zriedkavo mitotická aktivita (väčšinou len v nízko diferencovanej neuroepitelovej komponente)
- niekedy angiomatoidné cievy
- absencia mikrovaskulárnej proliferácie

MIKRO

- Anaplastické fokusy
  - Vysoká mitotická aktivita
  - Mikrovaskulárna proliferácia
  - Nekrózy s perfiérnym palisádovaním

„CELL OF ORIGIN“

- Hypotéza podľa ktorej ide o embryonálne tumory s progresívnou maturáciou
- Progenitorovou populáciou je pravdepodobne primitívna malobunková populácia exprimujúca gliálne aj neuronálne proteíny

GENTIKA

- Absencia genetických zmien typických pre difúzne astrocytómy
- BRAF V600E

PROGNÓZA

- kompletná resekcia spájaná s veľmi dobrou prognózou

1) 8 pacientov
   - 6 pacientov 15,1 roka
   - 2 pacienti umreli v perioperačnom období

Superficial Cerebral Astrocytoma Attached to Dura

Report of Six Cases in Infants

ANA LÍA TARATUTO, MD,*† JORGE MONGES, MD,† PEDRO LYLYK, MD,*†
AND RAMÓN LEIGUARDA, MD*

Reported are six cases of meningocerebral astrocytomas attached to dura, involving the superficial cortex, in infants under 1 year of age. They represent 1.25% of 483 intracranial tumors in infancy studied at the Children's Hospital in the last 12 years. Five were located in the frontal lobes, with variable extension to the parietal or the parietotemporal regions, and one was located in the parietal lobe. They were all composed of a solid portion and one or more cysts, and they measured approximately 6 to 12 cm in diameter. They had spindle cells, some more plump, arranged in areas in a storiform pattern. Tumors were very rich in reticulin fibers, mimicking a mesenchymal tumor. There was very slight pleomorphism. Bizarre giant cells were not observed and lipidization was not a prominent feature. Immunoperoxidase technique was performed in all of them and showed glial fibrillary acidic protein (GFAP) in most of the tumor cells. We believe their origin is from subpial astrocytes. They probably represent a separate entity whose diagnosis cannot be accurately established without immunohistochemical techniques.

Cancer 54:2505–2512, 1984.

2) 14 pacientov
   - 8,7 roka bez úmrtia a recidív

BRAIN PATHOLOGY

Desmoplastic Infantile Ganglioglioma and Desmoplastic Cerebral Astrocytoma of Infancy

Scott R. VandenBerg

First published: July 1993 | https://doi.org/10.1111/j.1750-3639.1993.tb00754.x | Cited by:70

PROGNÓZA

- Subtotálna resekcia
  - stabilita
  - pomalý rast
  - regresia

Postoperative Regression of Desmoplastic Infantile Gangliogliomas: Report of Two Cases.
Takeshima, Hideo M.D.; Kawahara, Yoshihiro M.D.; Hirano, Hirofumi M.D.; Obara, So-ichi M.D.; Niiro, Masaki M.D.; Kuratsu, Jun-ichi M.D.
[Report] *Neurosurgery.* 53(4):979-984, October 2003.

(Format: HTML, PDF)

OBJECTIVE AND IMPORTANCE: Desmoplastic infantile gangliogliomas (DIGs) are extremely rare tumors that respond well to treatment. However, their biological behavior remains to be clarified. We describe two patients whose DIGs spontaneously regressed after surgery, without adjuvant therapy.

CLINICAL PRESENTATION: A 9-month-old girl presented with left hemiparesis, and a 6-month-old boy presented with increasing head circumference. For both patients, neuroimaging demonstrated a huge cystic tumor that included a solid portion and was widely attached to the dura. Gadolinium-diethylenetriamine penta-acetic acid produced strong enhancement.

INTERVENTION: One patient underwent partial and the other subtotal tumor removal. Histologically, both tumors were diagnosed as DIGs. Postoperatively, the residual tumors were monitored without adjuvant therapy, and both regressed in several months.

CONCLUSION: Our experience suggests that DIGs may include a subgroup of tumors with a tendency for spontaneous regression, possibly attributable to the induction of apoptosis.

Copyright (C) by the Congress of Neurological Surgeons

PROGNÓZA

- Aj tumory s anaplastickou komponentou majú v drvivej väčšine dobrú prognózu po totálnej resekcii

- Progresia tumoru je vzácny fenomén, najčastejšie
  - U tumorov ktoré nemôžu byť kompletne odstránené
  - U tumorov s vysokým proliferačným indexom
  - U tumorov s anaplastickou morfológiou

- Niekedy reukuruje ochorenie ako glioblastóm

Ďakujem za pozornosť